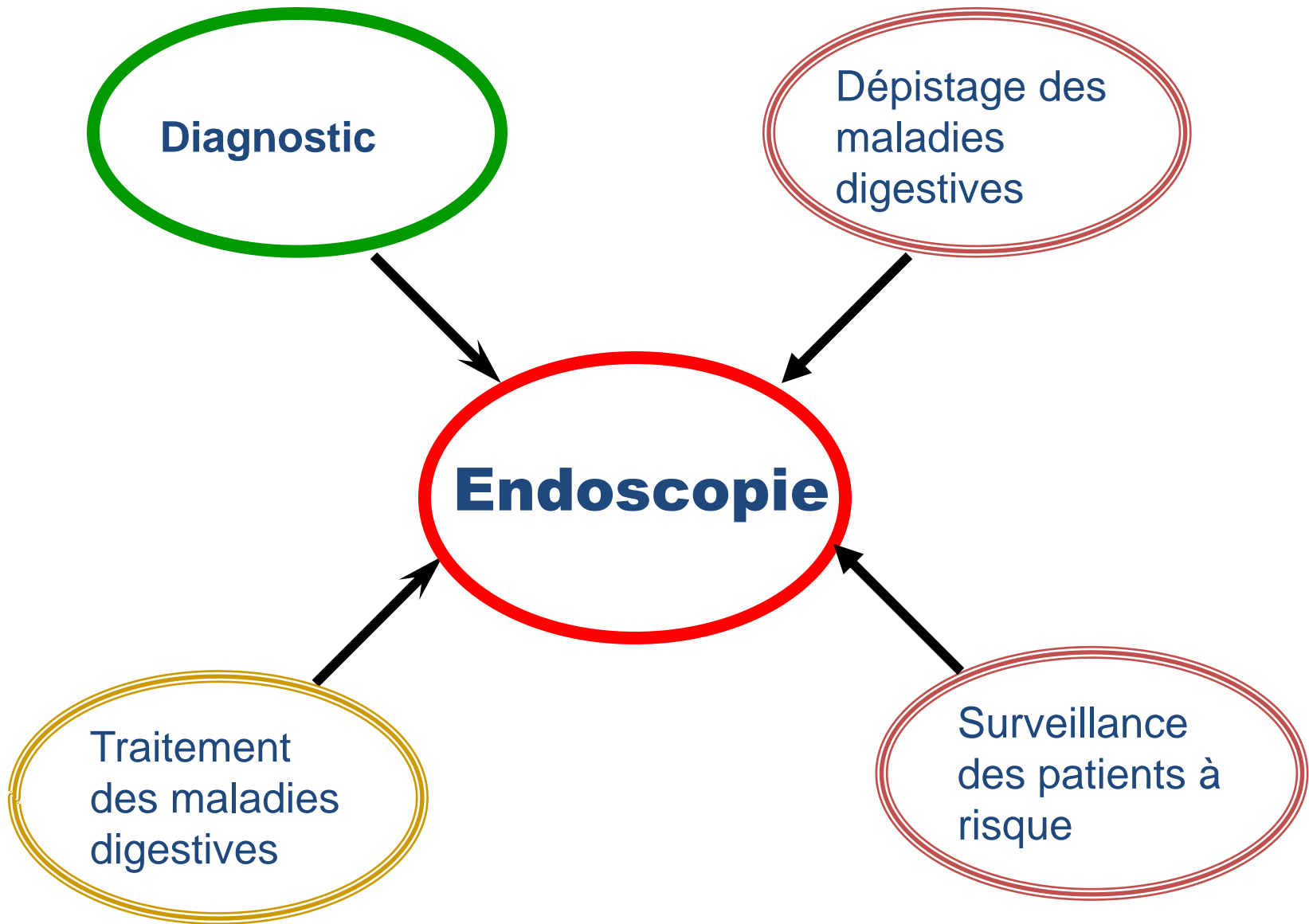


# Endoscopie – le passé le présent et le futur

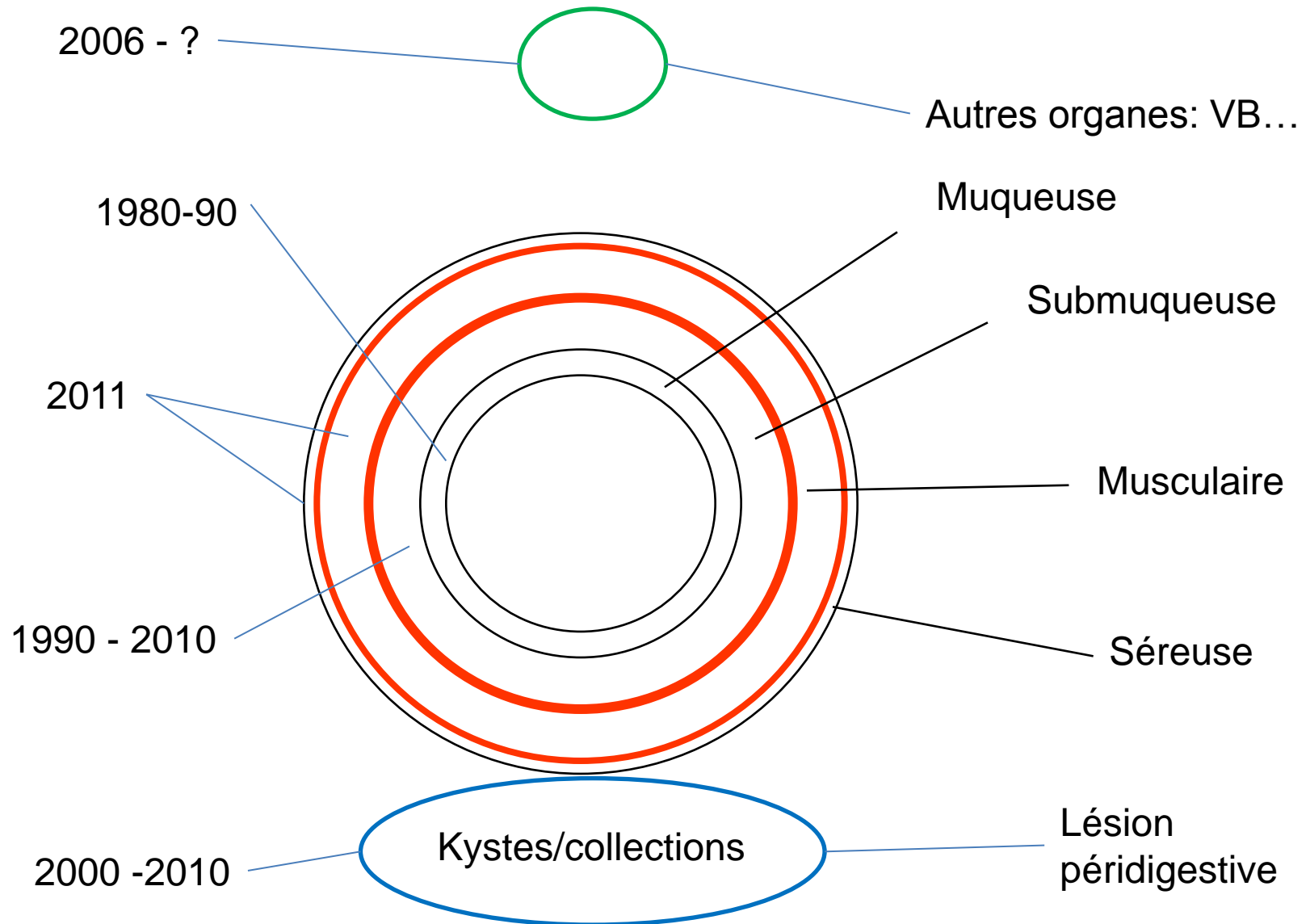
Prof. Gian Dorta  
Service de Gastro-entérologie et  
d'Hépatologie  
CHUV Lausanne

# Endoscopie digestive

- 1978 Endoscopie souple      Diagnostic
  - 1982 Polypectomie
  - ERCP
  - Mucosectomie
  - ESD
  - Etc..
- ↓
- Thérapie



# Tractus digestif: les cibles



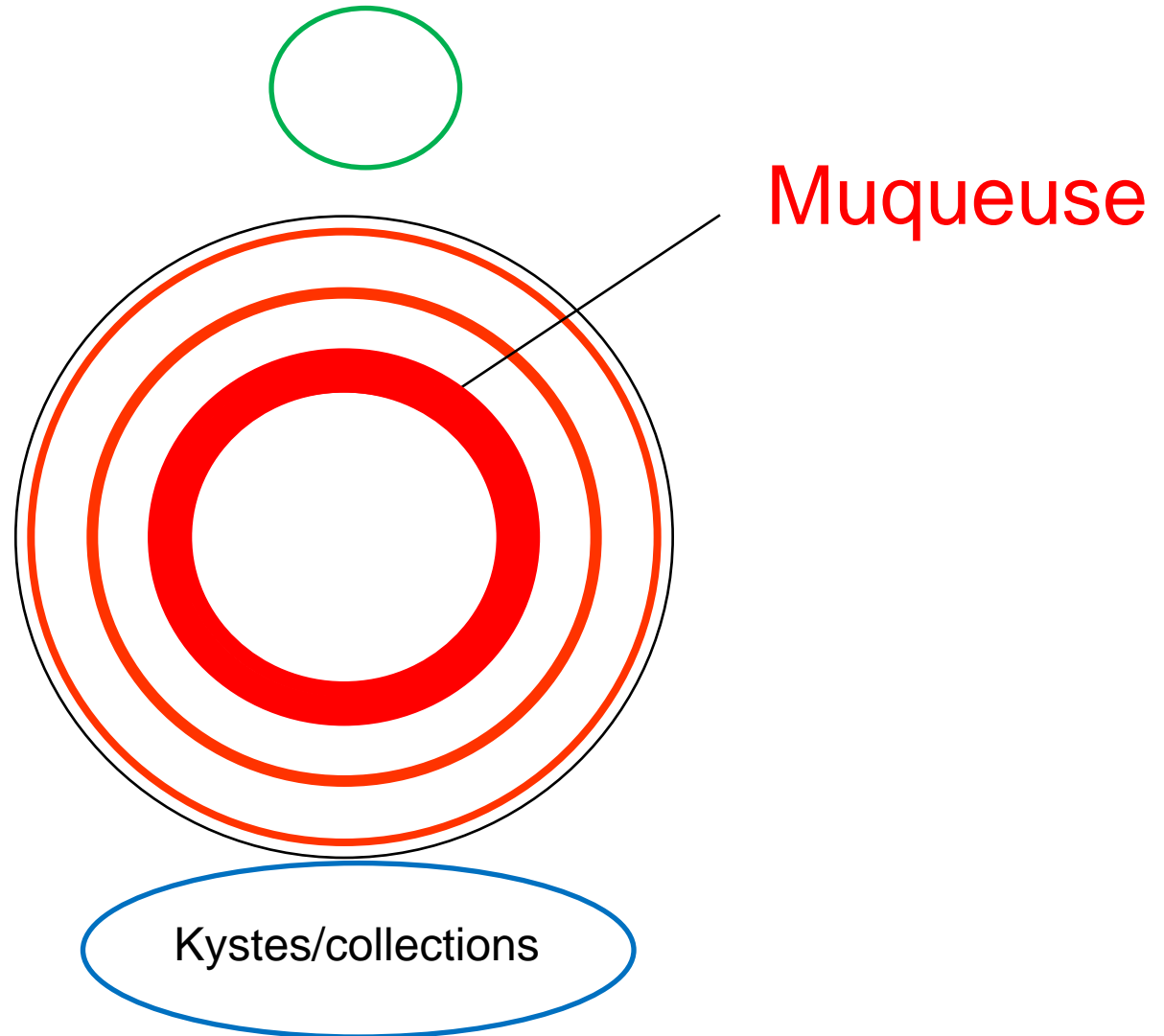
# Diagnostic

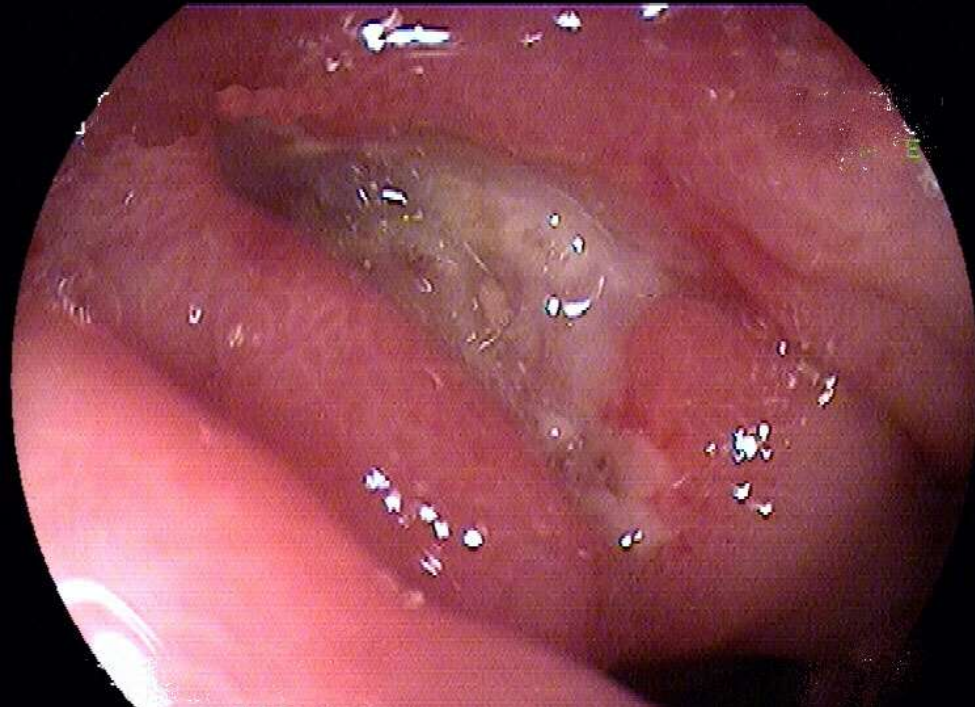- Non Invasif
  - Inspection visuelle
  - Chromo-endoscopie
  - Fice/i-scan/NBI
  - Endosonographie
- Invasif
  - Biopsie pince
  - Biopsie à l'anse
  - Ponction cytologique ou mini-histologie

# Diagnostic

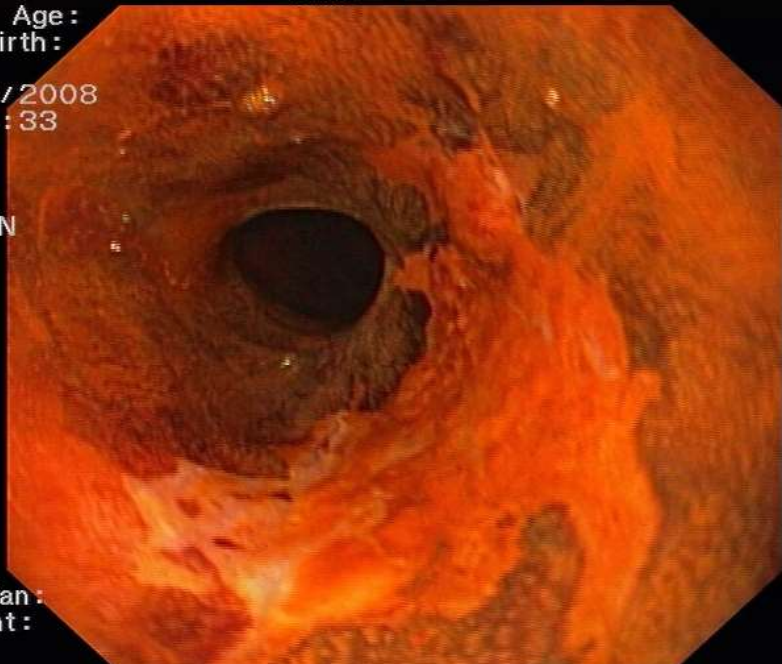
- **Non Invasif**
  - Inspection visuelle
  - Chromo-endoscopie
  - Fice/i-scan/NBI
  - Endosonographie
  - OCT/Confocal 2010
- **Invasif**
  - Biopsie pince
  - Biopsie à l'anse
  - Ponction cytologique ou mini-histologie

# Tractus digestif





No. :  
Age :  
D. Birth :  
/09/2008  
:54:33  
P: 1  
F:  
Gr:N

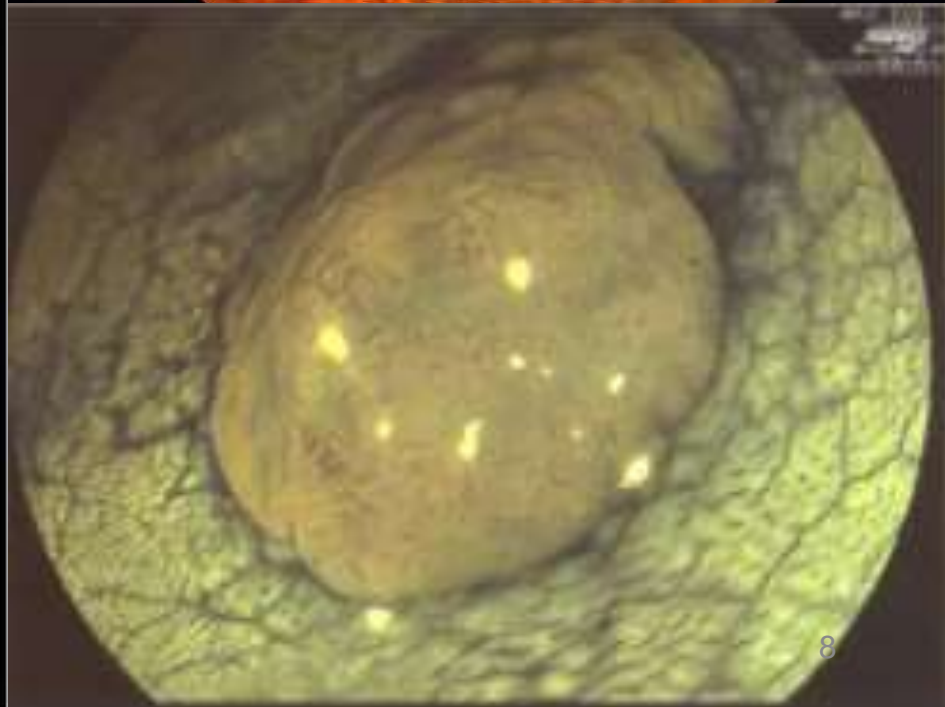

Physician :  
Department :

NAME  
ID  
1

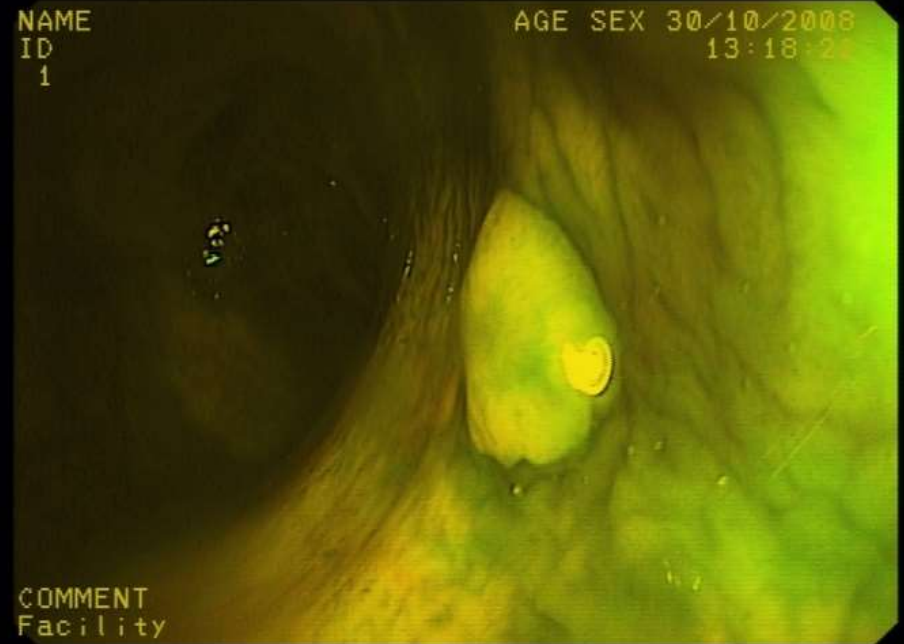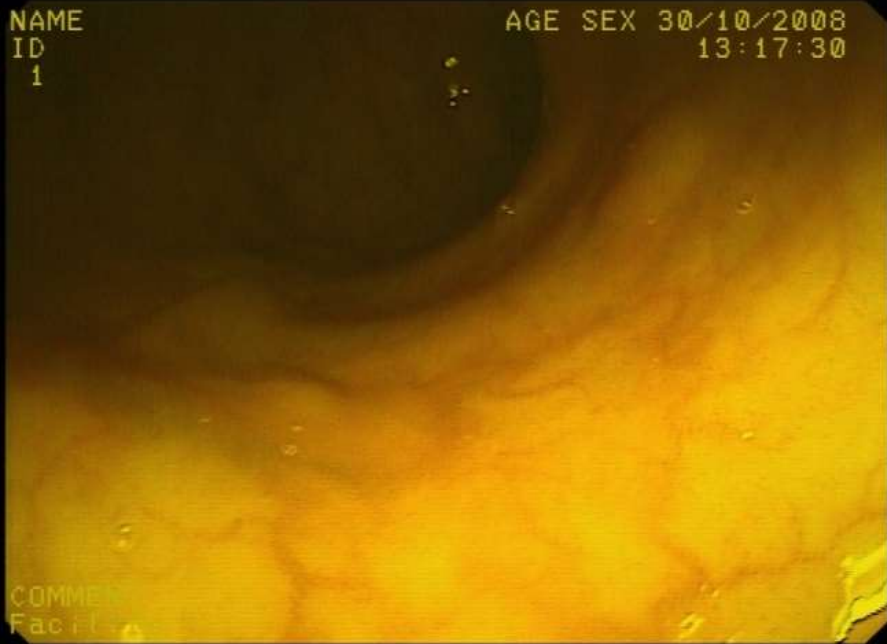AGE SEX 30/10/2008  
13:17:30

COMMENT  
Fac 1

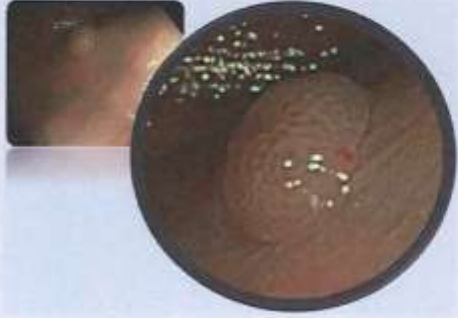






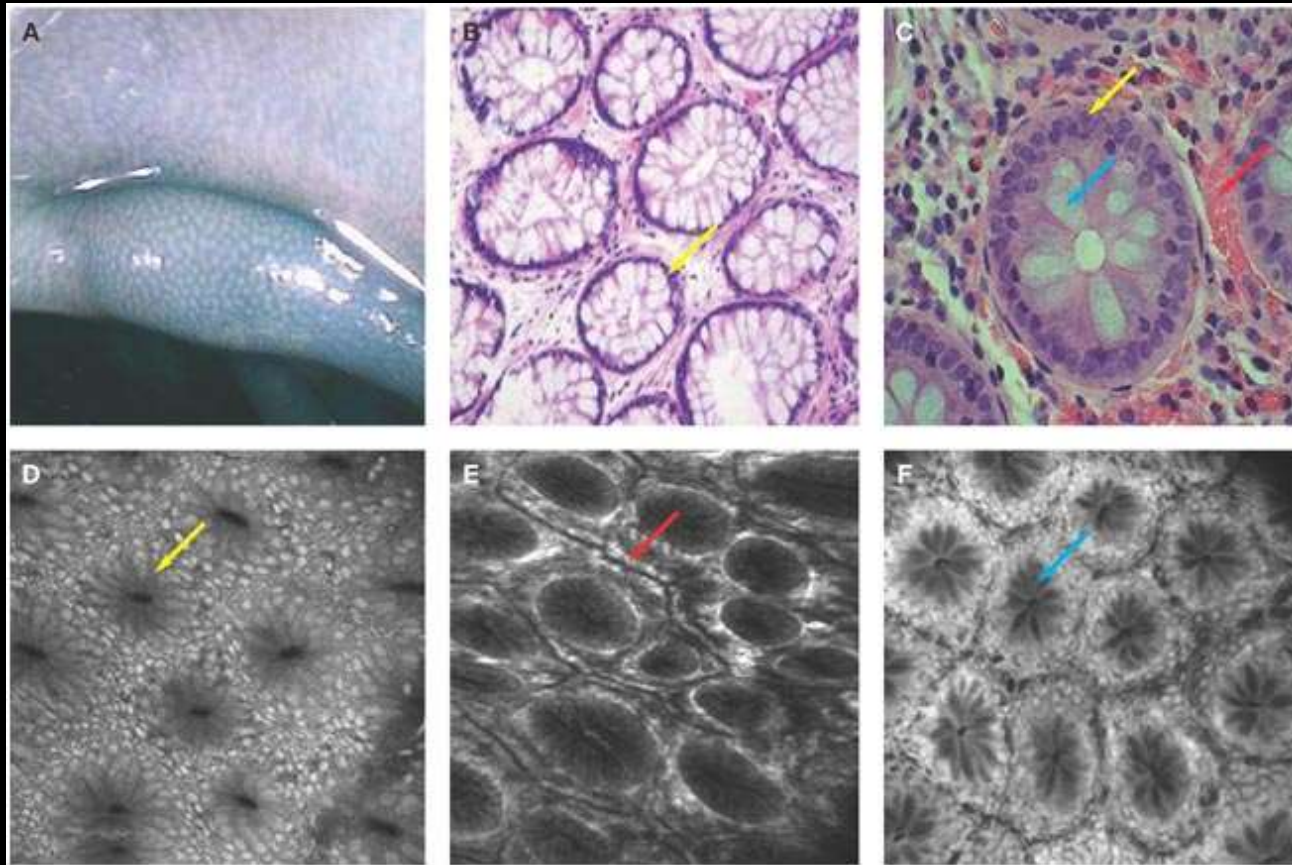
# Colorants: Indigo



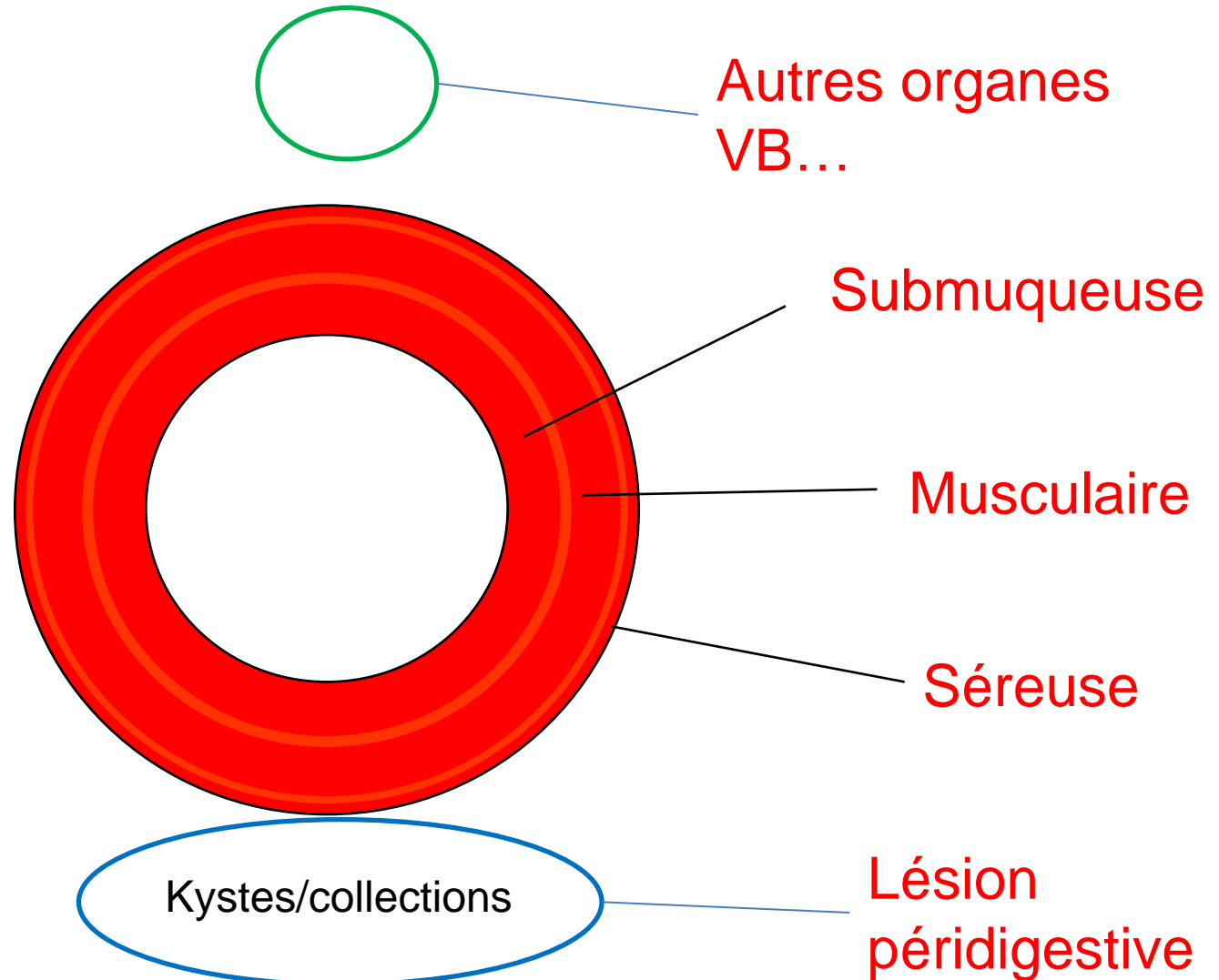
# FICE I-scan NBI

	Type 1	Type 2	Type 3
<i>Sample image</i>			
<b>Color</b>	Same or lighter than background	Browner relative to background (verify color arises from vessels)	Brown to dark brown relative to background; sometimes patchy whiter areas
<b>Vessels</b>	None, or isolated lacy vessels may be present coursing across the lesion	Brown vessels surrounding white structures	Has area(s) of disrupted or missing vessels
<b>Surface Pattern</b>	Dark or white spots of uniform size, or homogeneous absence of pattern	Oval, tubular or branched white structures surrounded by brown vessels	Amorphous or absent surface pattern
<i>Most likely pathology</i>	Hyperplastic	Adenoma	Deep submucosal invasive cancer

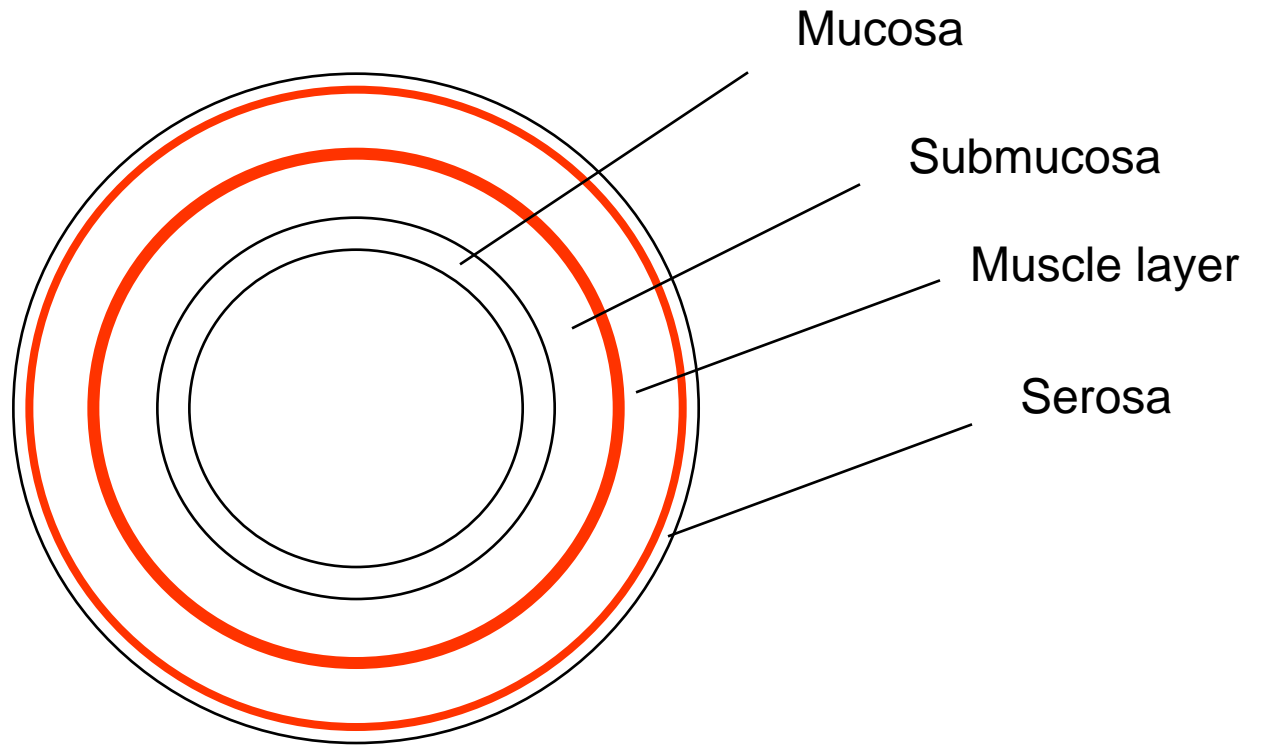
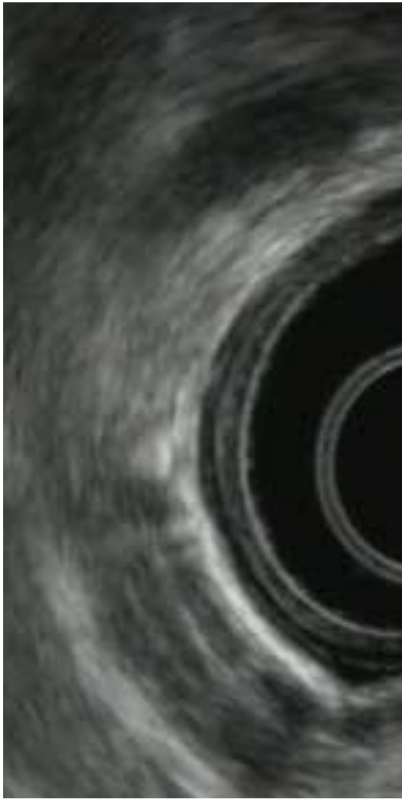
# Confocal endoscopy



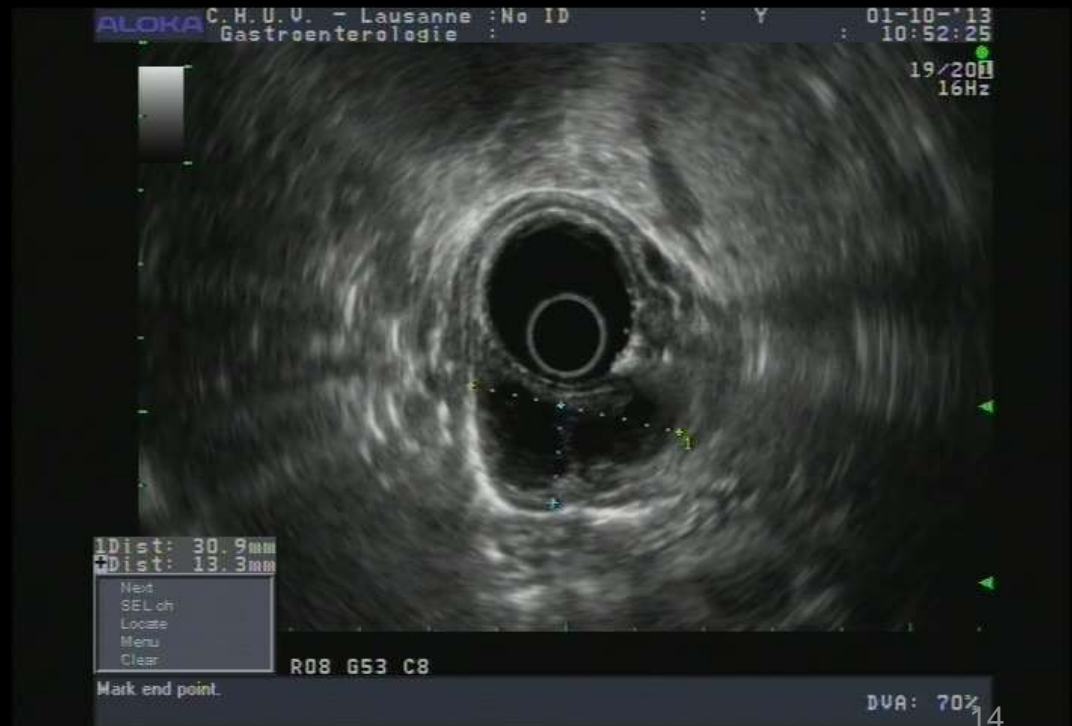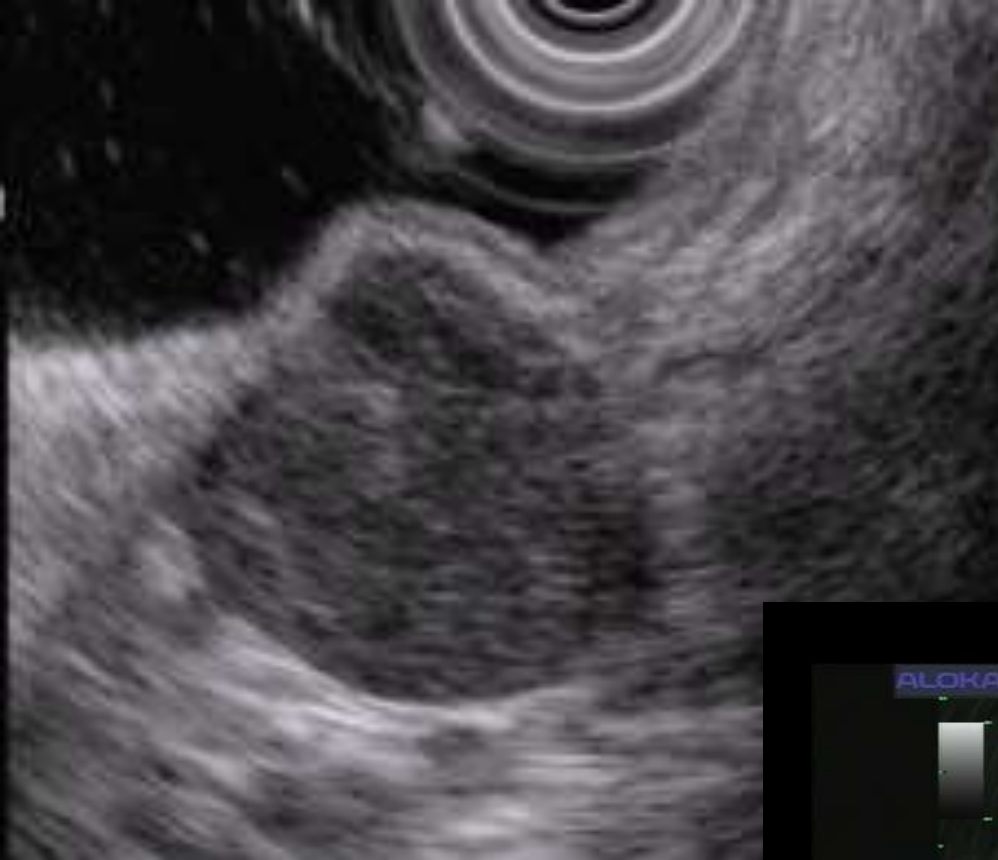# Tractus digestif

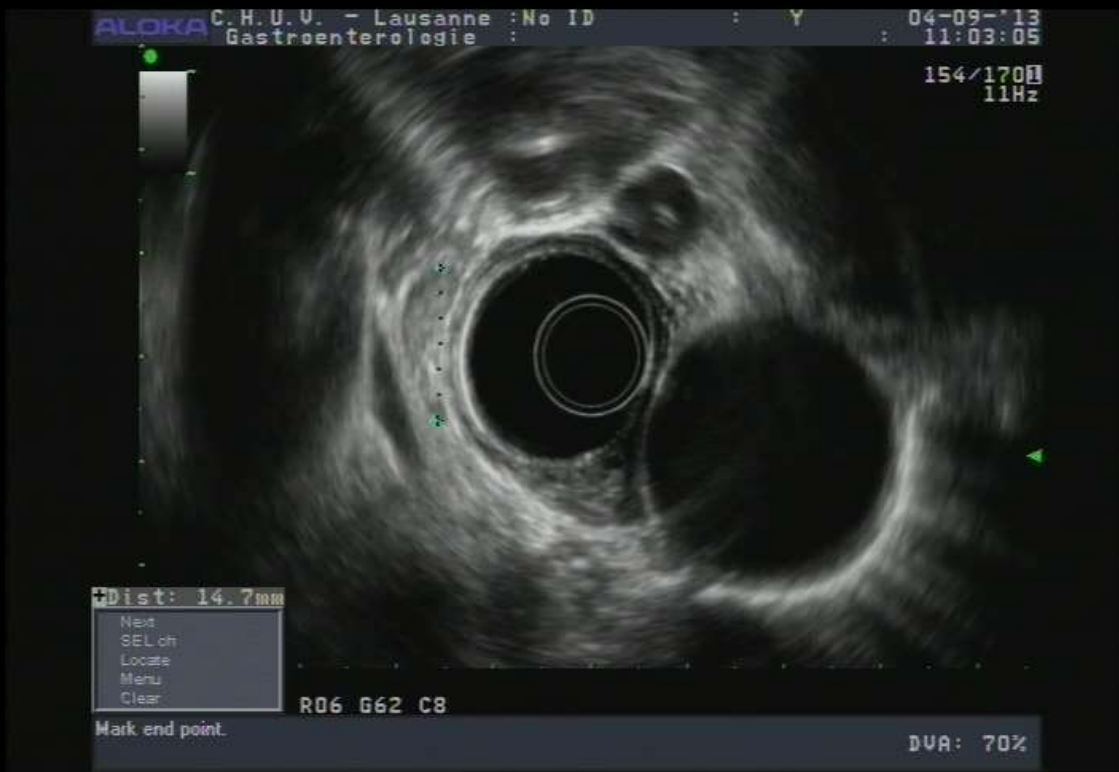
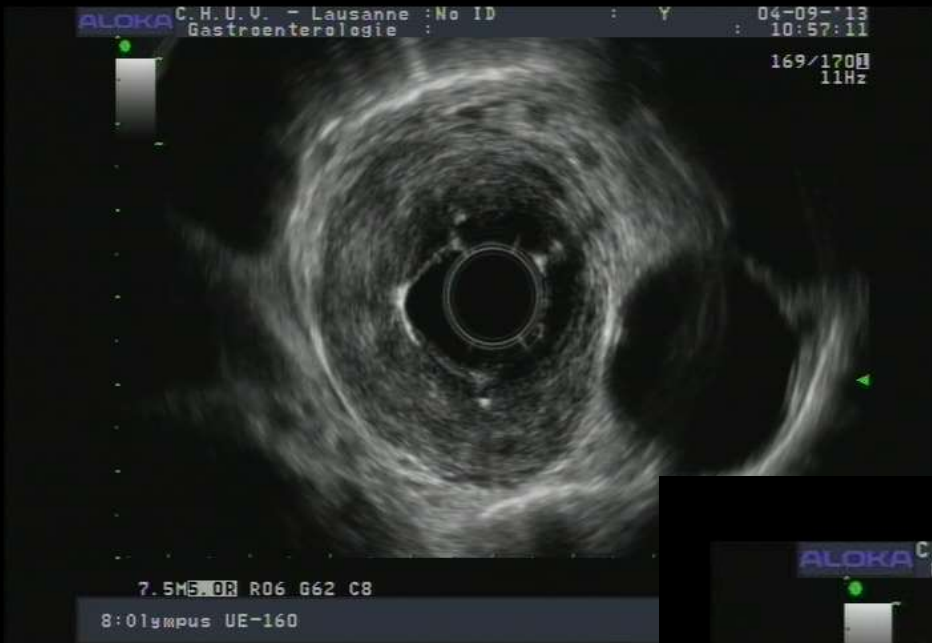
# Endosonographie: paroi digestive

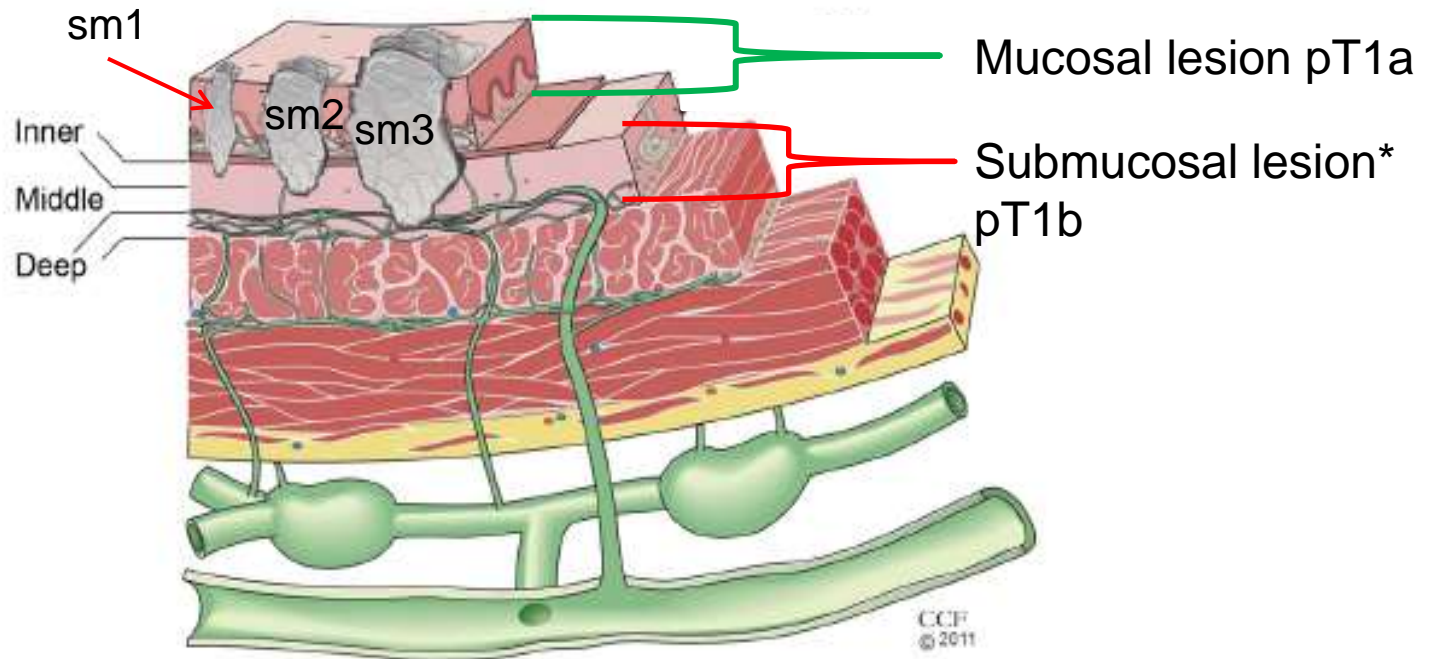


# Tumeur submuqueuse oesophagienne





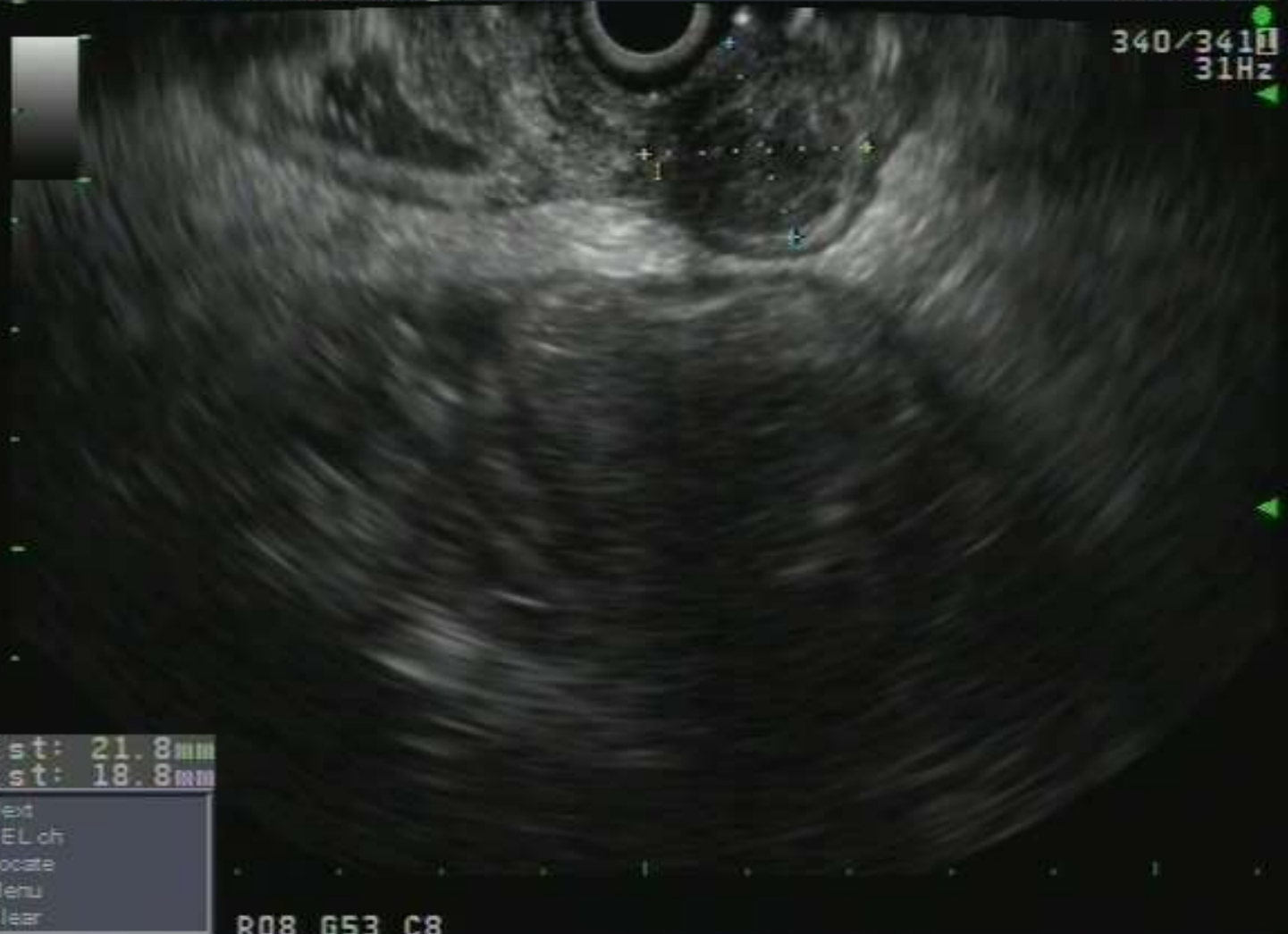# Limites: oesophagus



\* Risque de métastase ganglionnaire > 10 % (sm 1 à 3)

Raja S, J Thorac Cardiovasc Surg 2011;142(6):1403-11.e1





1Dist: 21.8mm  
2Dist: 18.8mm

- Next
- SEL ch
- Locate
- Menu
- Clear

R08 653 C8

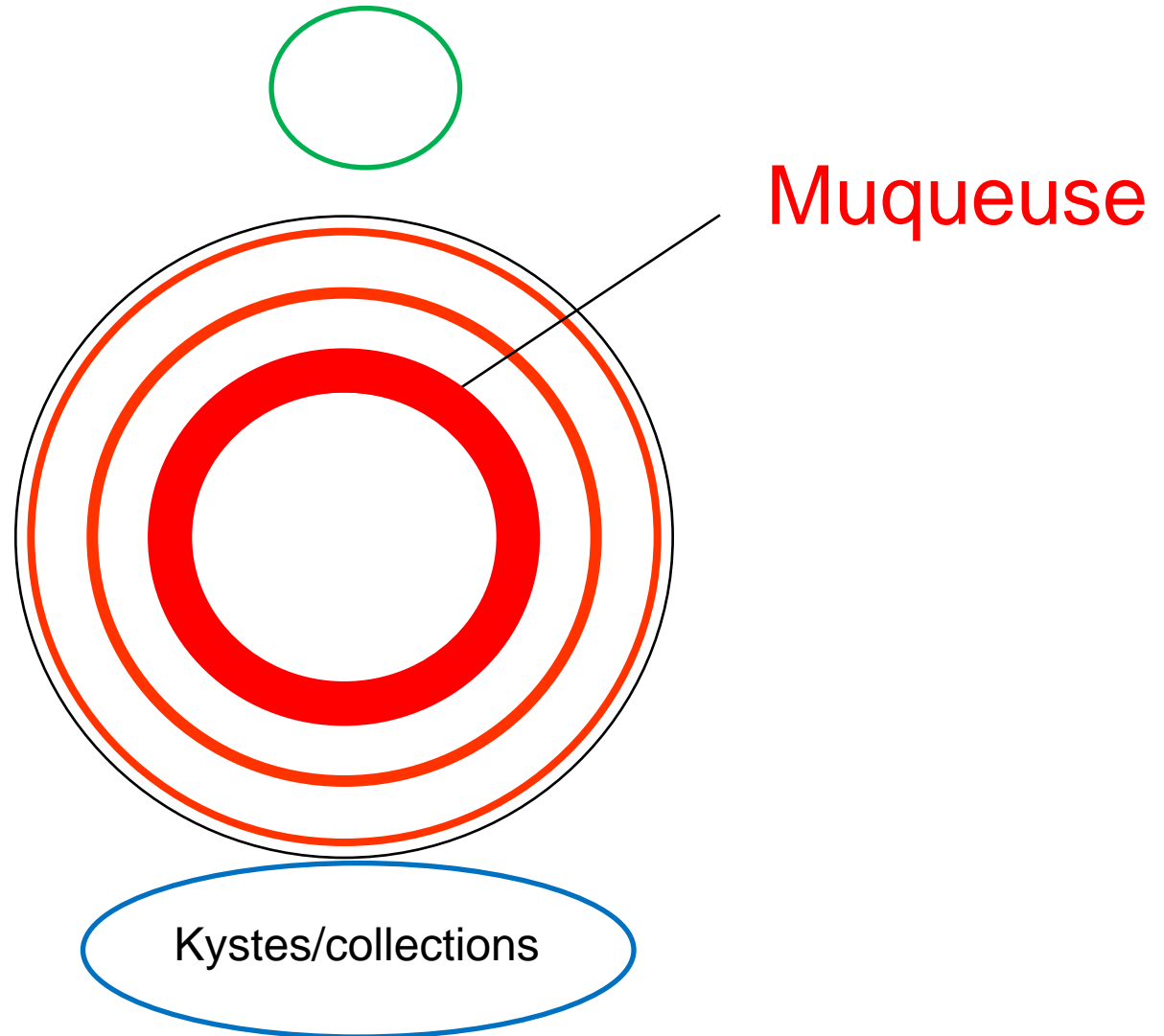
Mark end point.

DVA: 70%

# DiagnostiC

- Non Invasif
  - Inspection visuelle
  - Chromo-endoscopie
  - Fice/i-scan/NBI
  - Endosonographie
- Invasif
  - Biopsie pince
  - Biopsie à l'anse
  - Ponction cytologique ou mini-histologie

# Tractus digestif



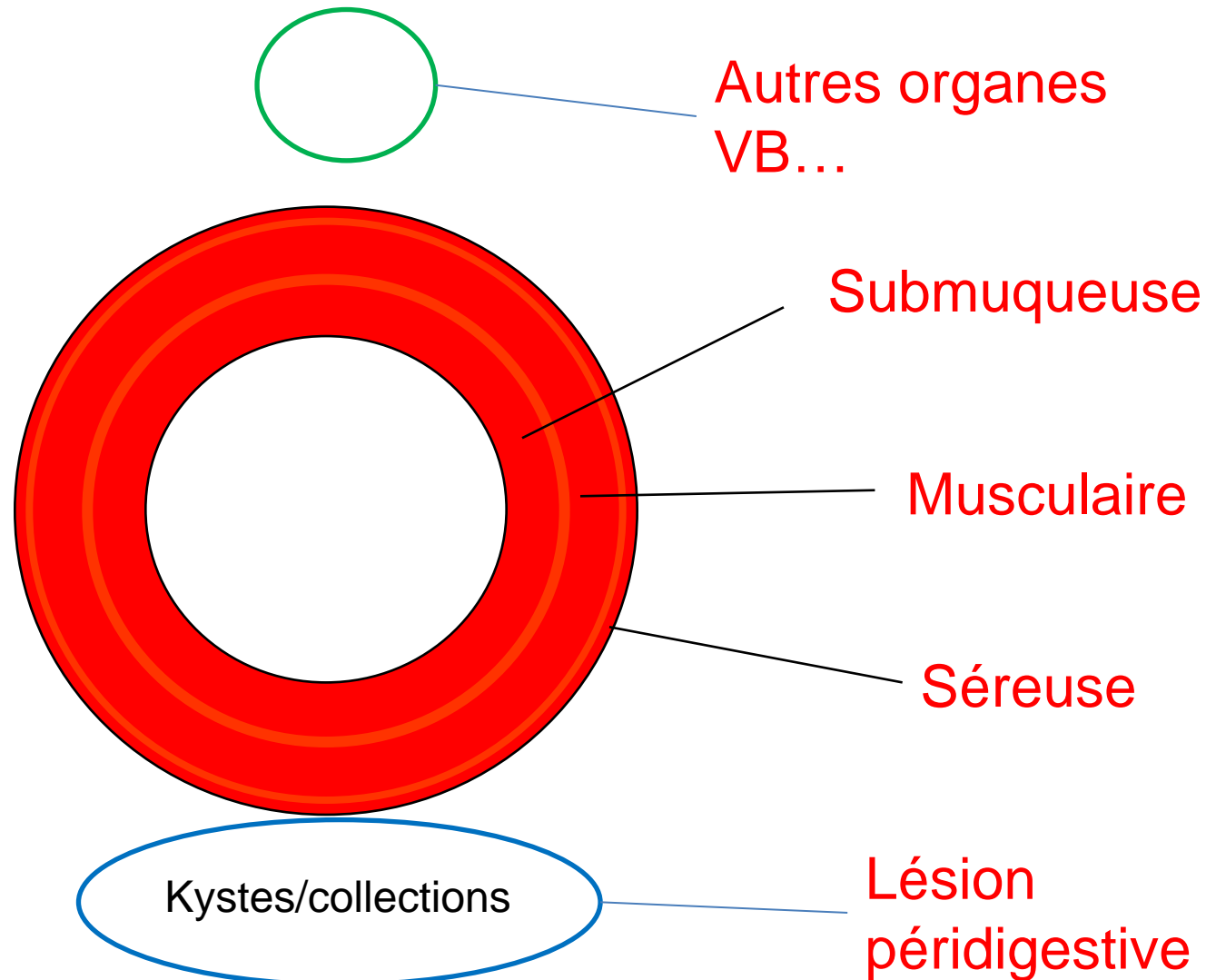
NAME  
ID  
1

AGE

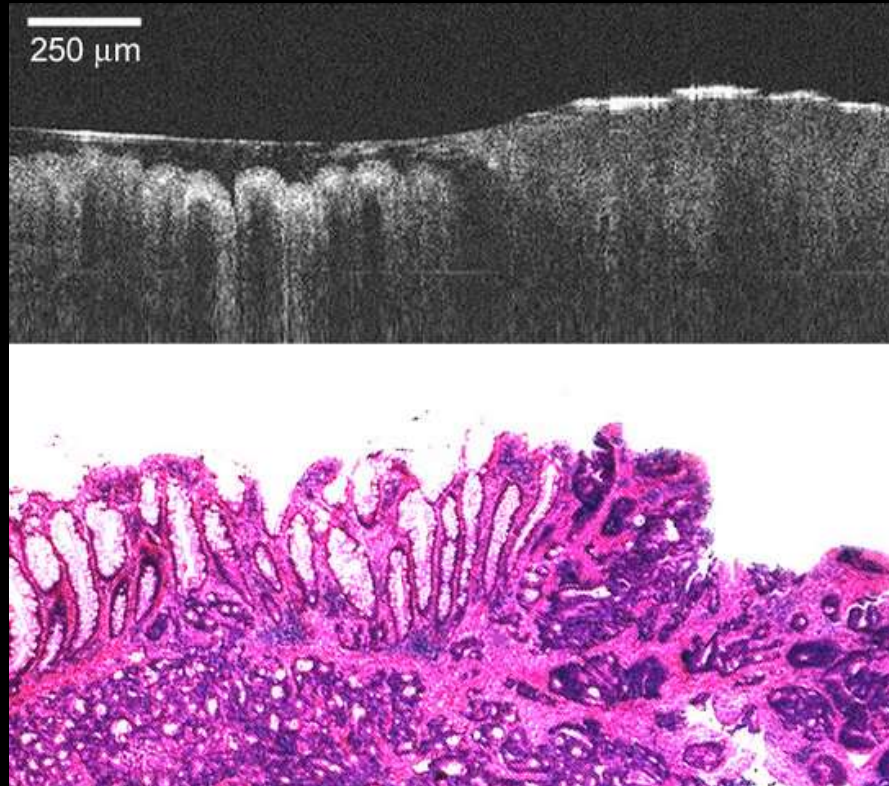
01/oct/2013  
09:47:57

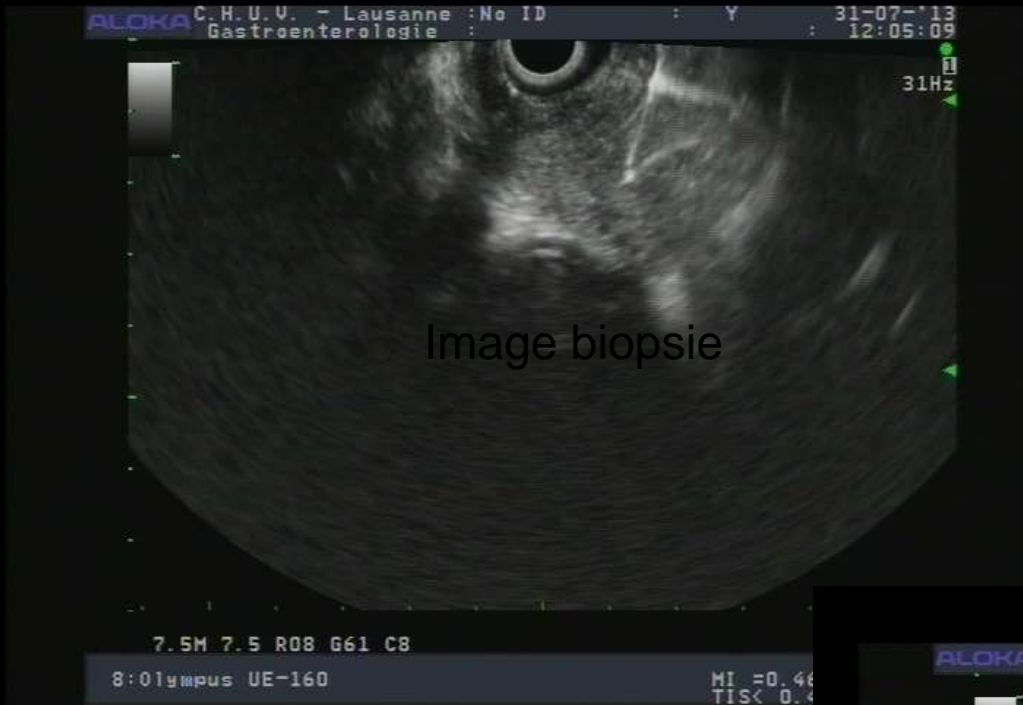COMMENT  
Dr  
CHUV Lausanne

# Tractus digestif

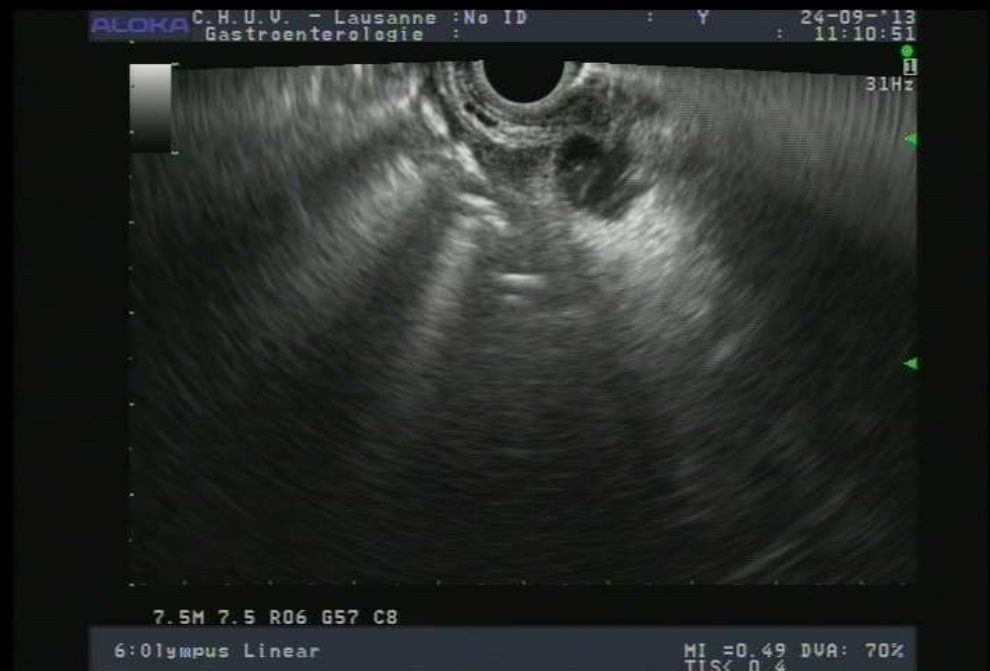

# OCT





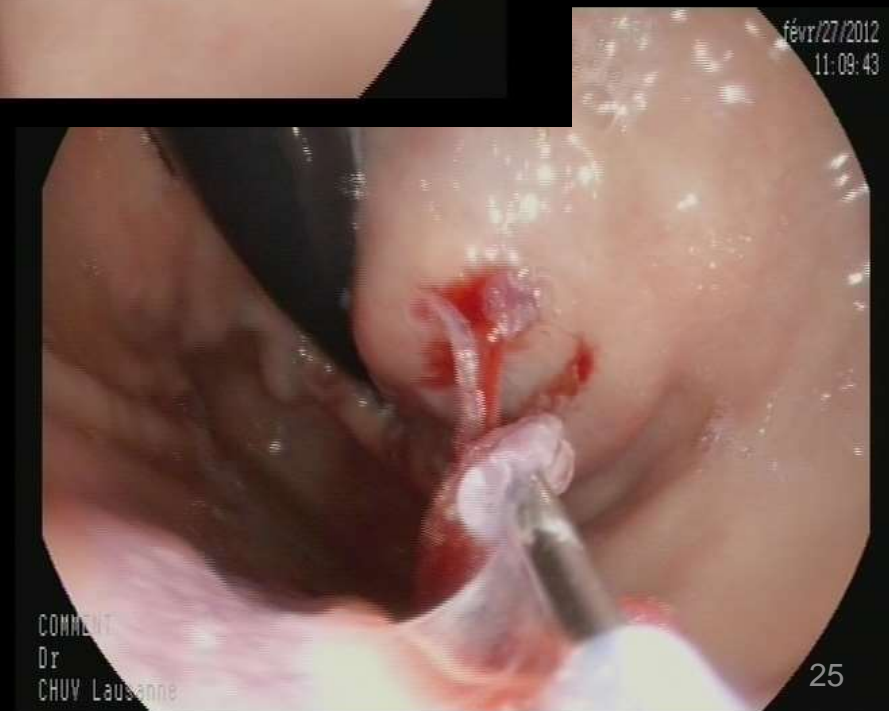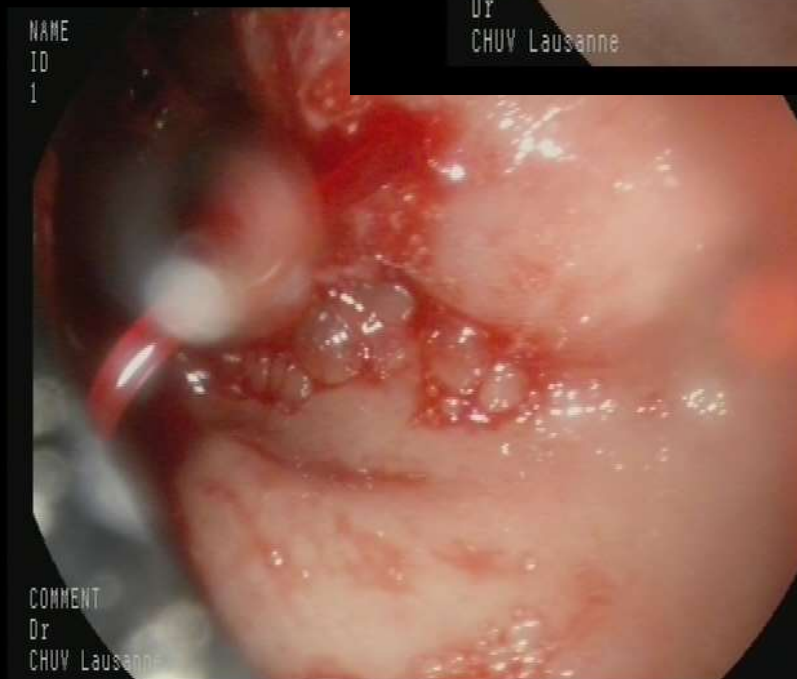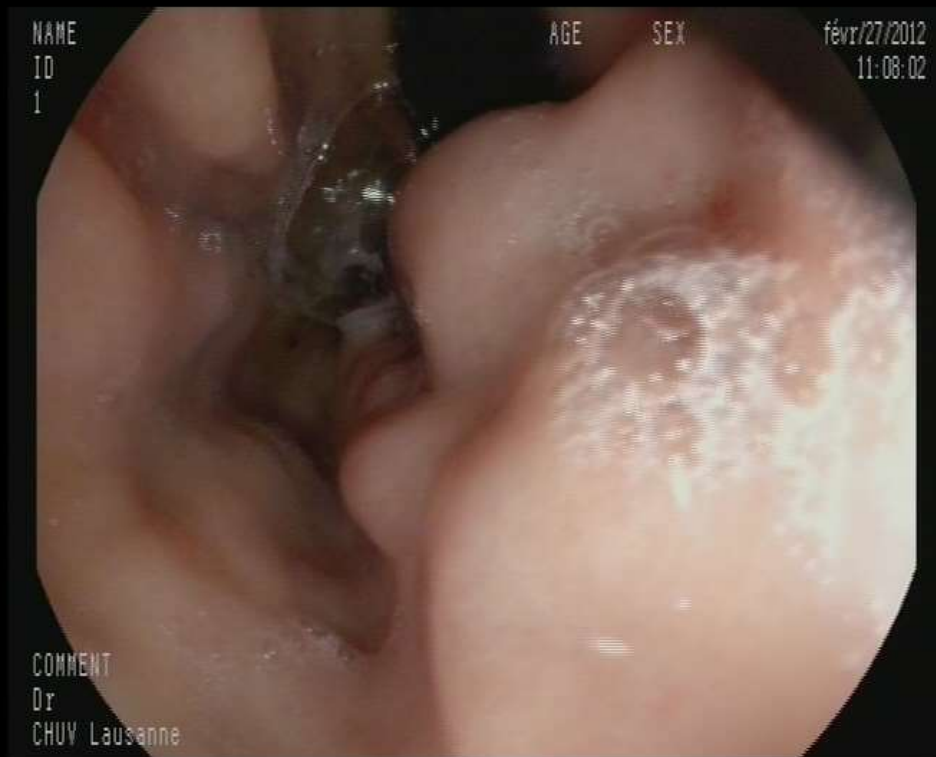## Cytoponction/ Mini-histologie/ Marqueurs tumoraux



# Traitements endoscopiques

- Hémorragie
- Sténose
- Polypectomie/mucosectomie
  - Œsophage (Barrett), estomac, intestin grêle, côlon)
- Pathologies biliaires
- Reflux gastro-oesophagien ( abandonné)
- Palliation (prothèse)
- Nutrition PEG/PEJ
- Ttt fistule /perforation





u xz1111

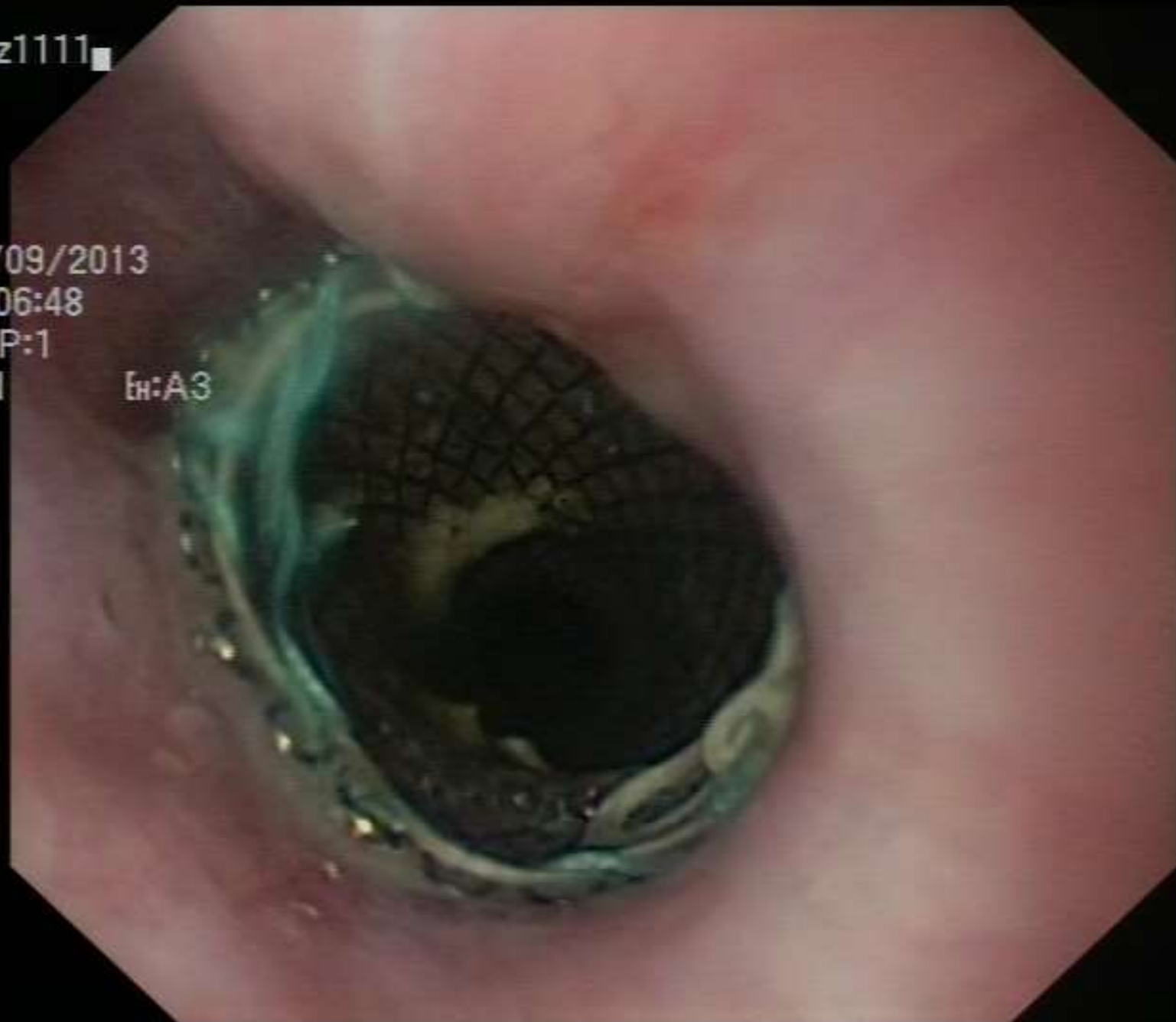20/09/2013

15:06:48

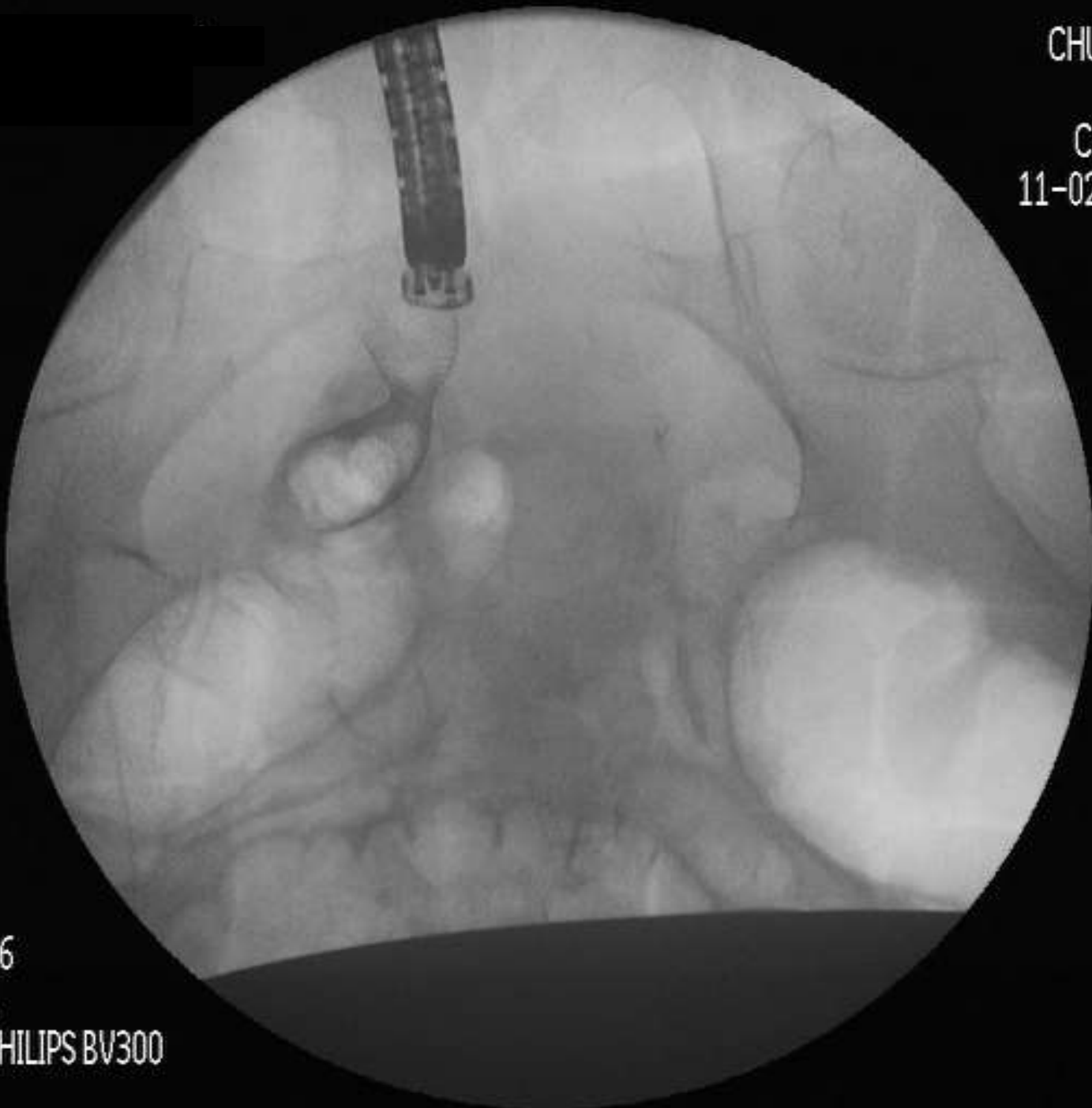
CVP:1

Gr:N

En:A3

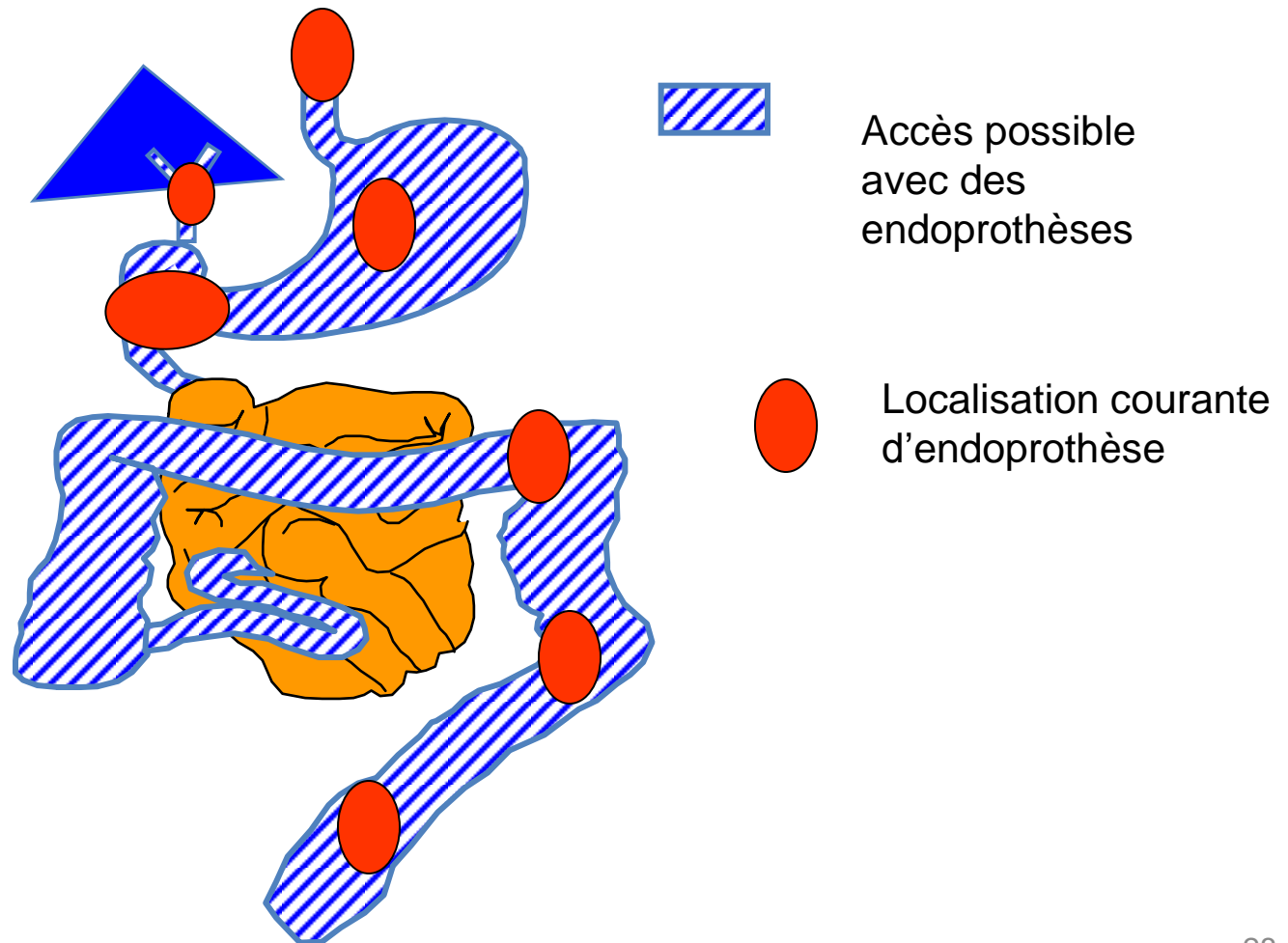


CHUV - Lausanne  
DORTA GIAN  
COLONOSCOPIE  
11-02-2004 16:08



26  
1  
PHILIPS BV300

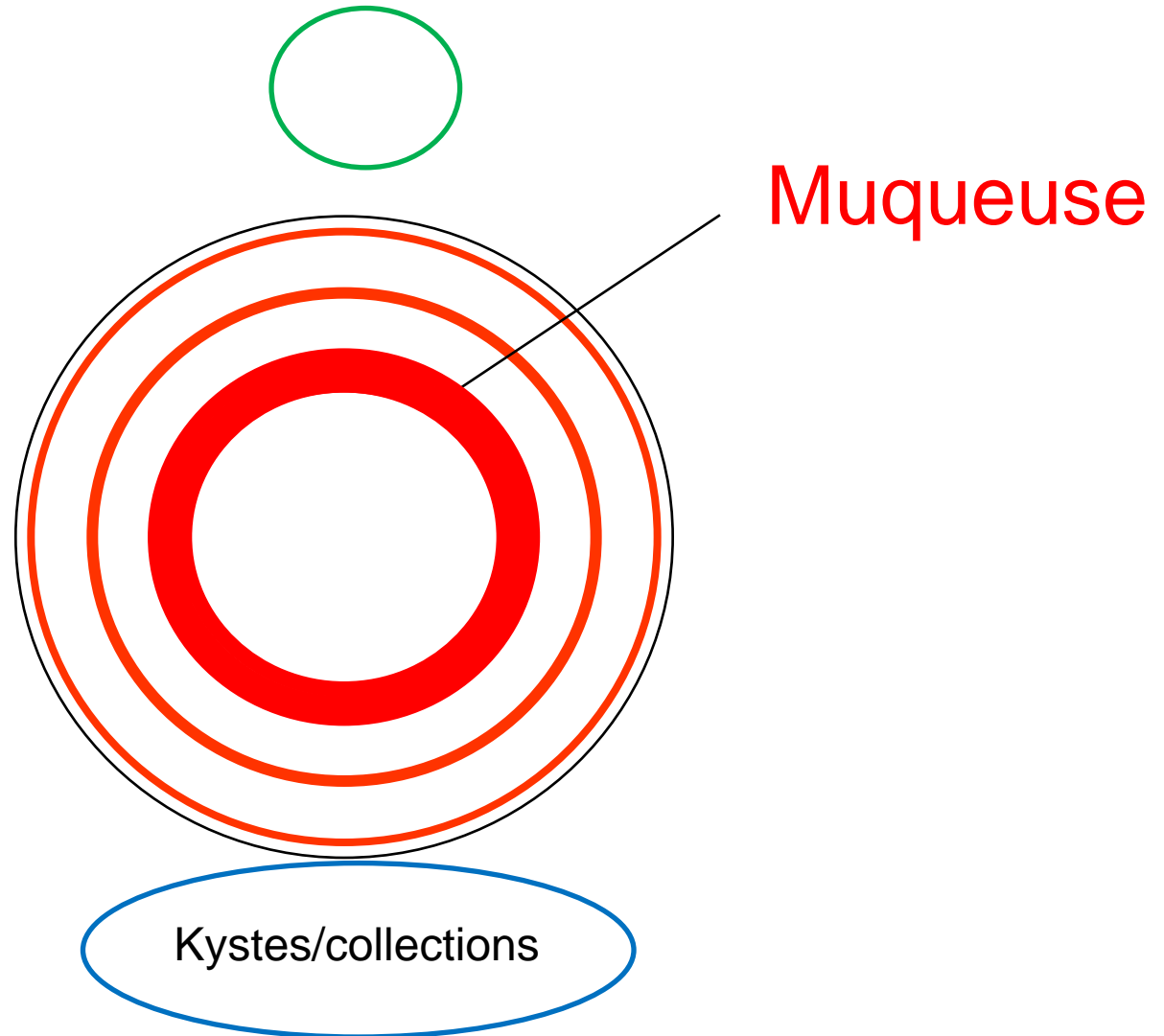
# Palliation par endoprothèse: Où?



# Techniques de résection endoscopique

- Polypectomie
  - lésions pédiculées
- Résection de la muqueuse (EMR)
  - lésions sessiles
- Résection par la submuqueuse (ESD)
  - lésions submuqueuses ou lésions sessiles ulcérées
- Résection de la paroi
  - lésions fixées à la submuqueuse

# Tractus digestif



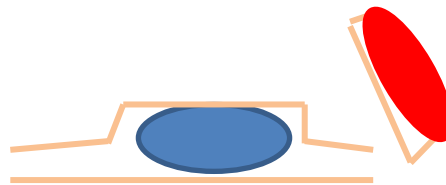
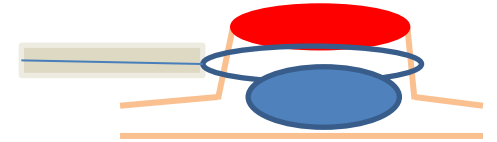
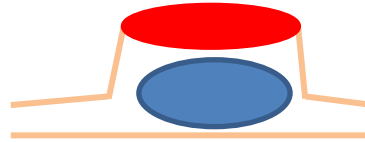
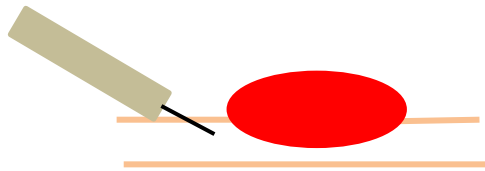
AGE SEX 17/02/2006  
16:05:25

ID  
1

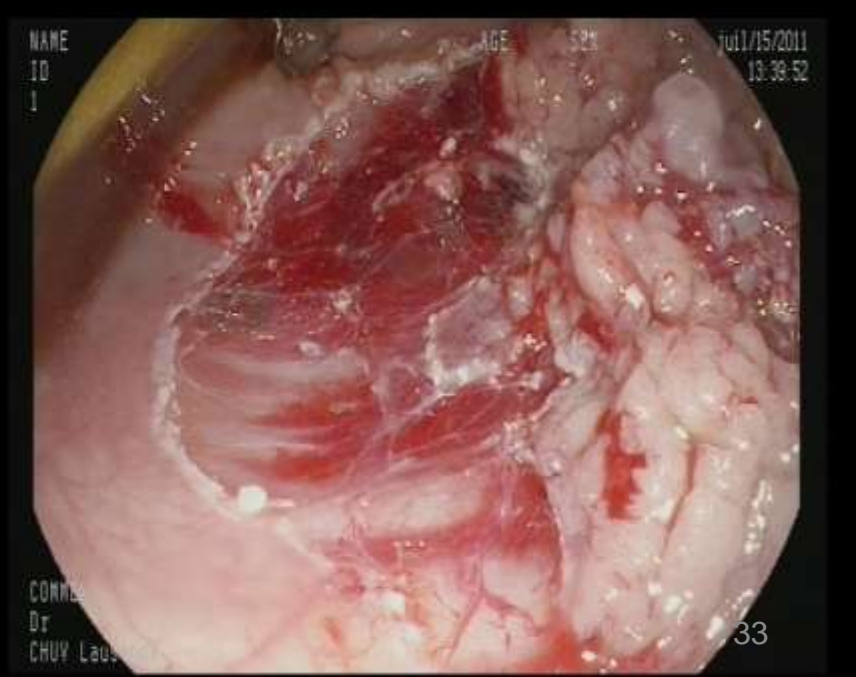
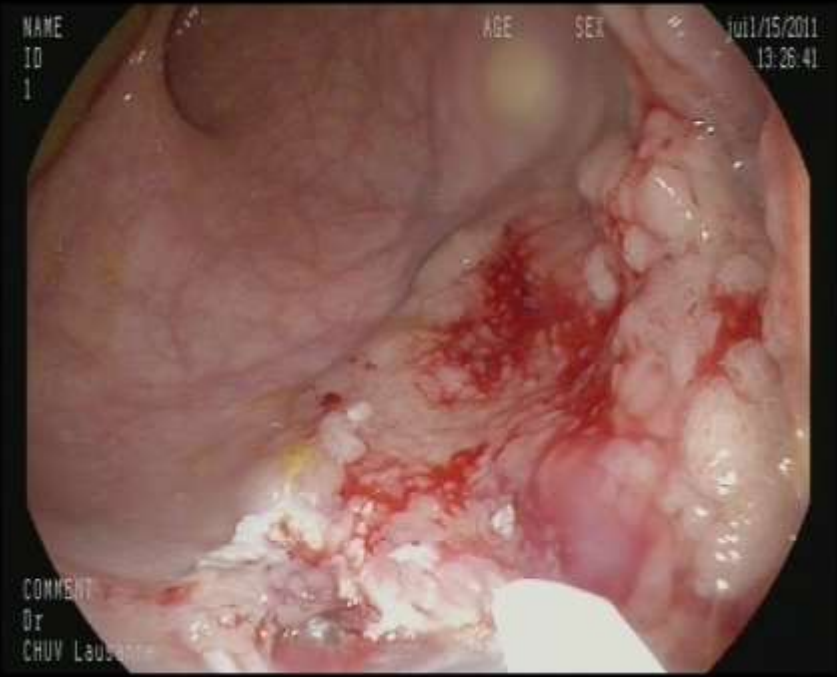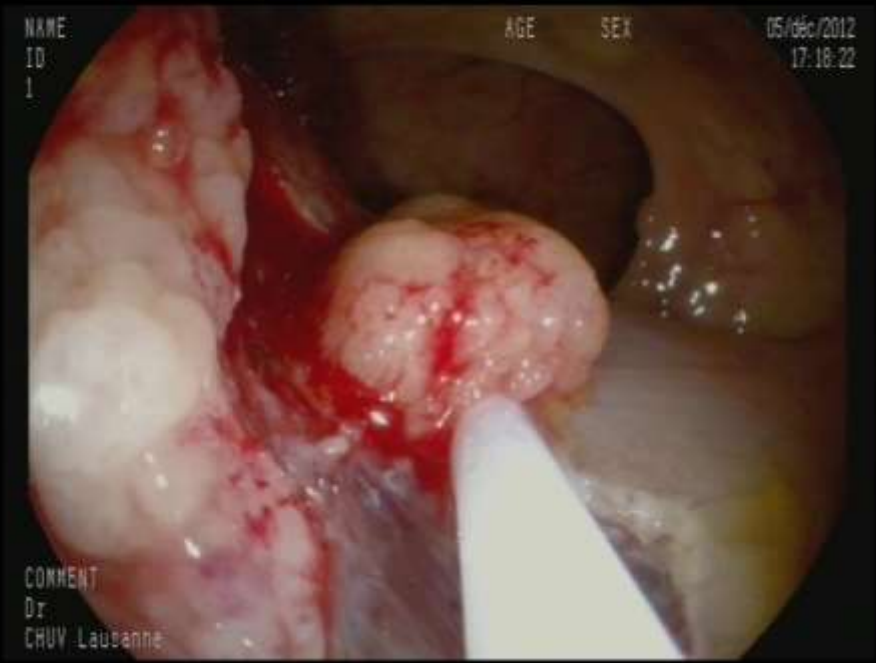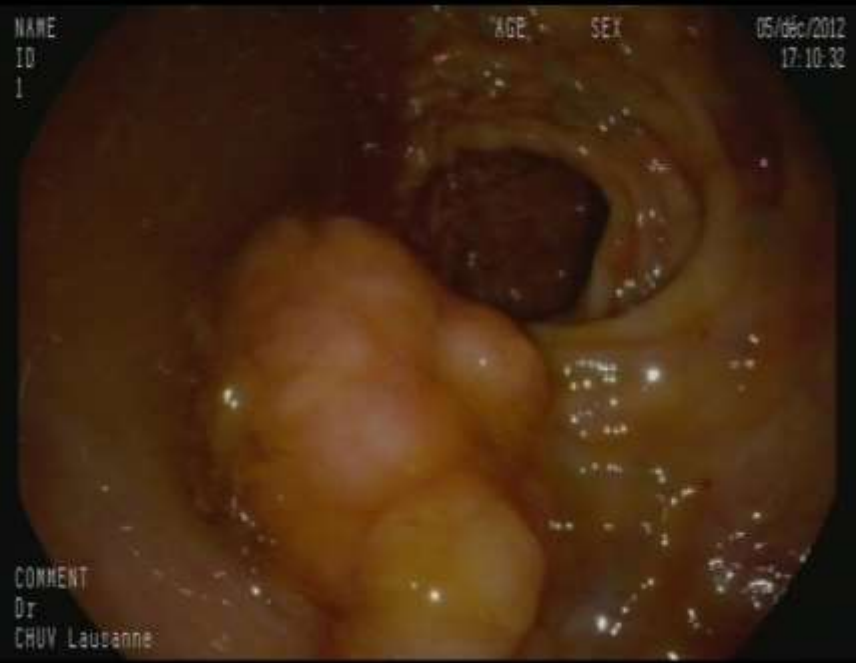COMMENT  
Facility

Dr.

# Résection de la muqueuse







ID. No. : ■

Name :

Sex : Age :

D. O. Birth :

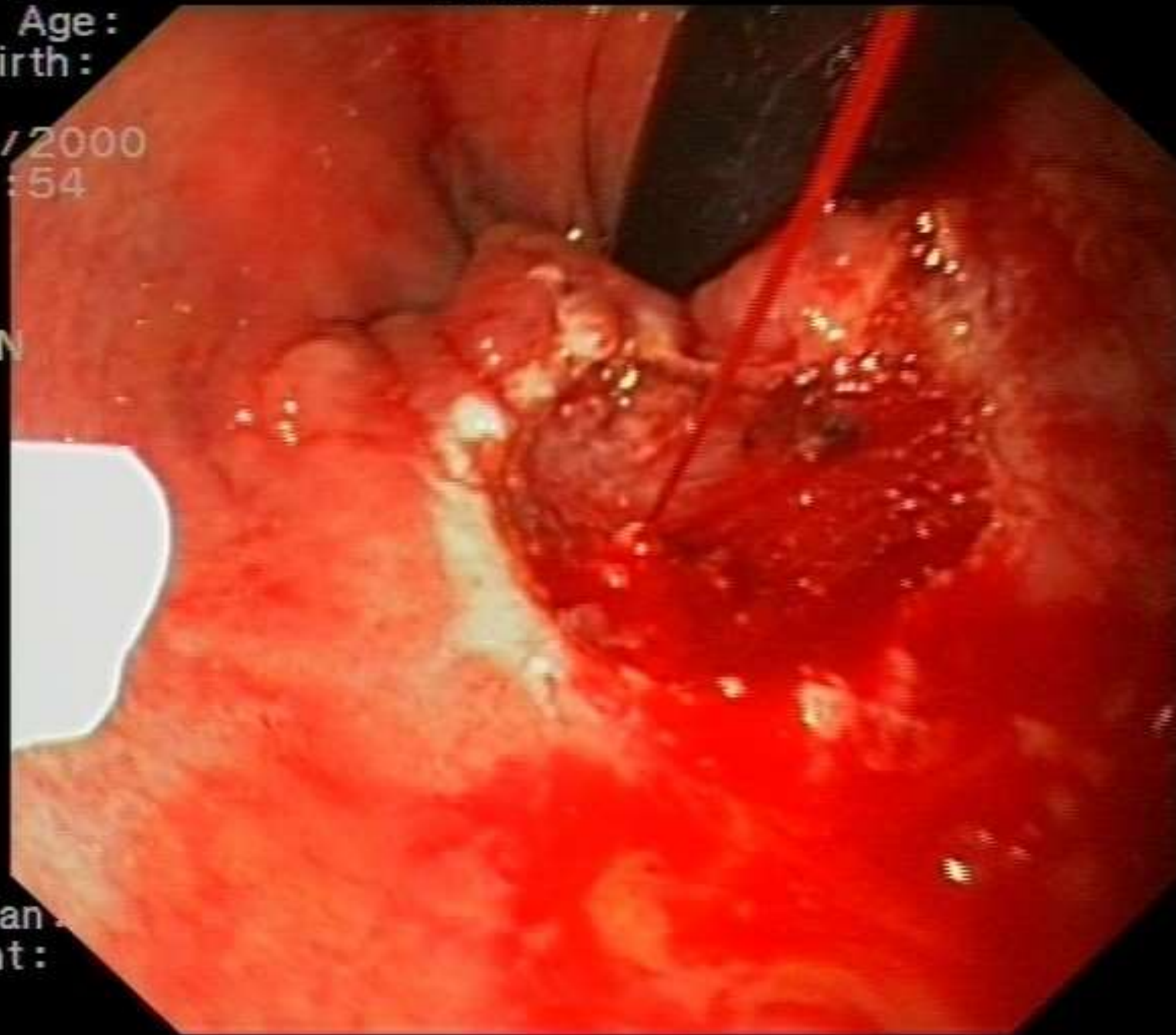
01/01/2000

00:41:54

CVP :

D. F :

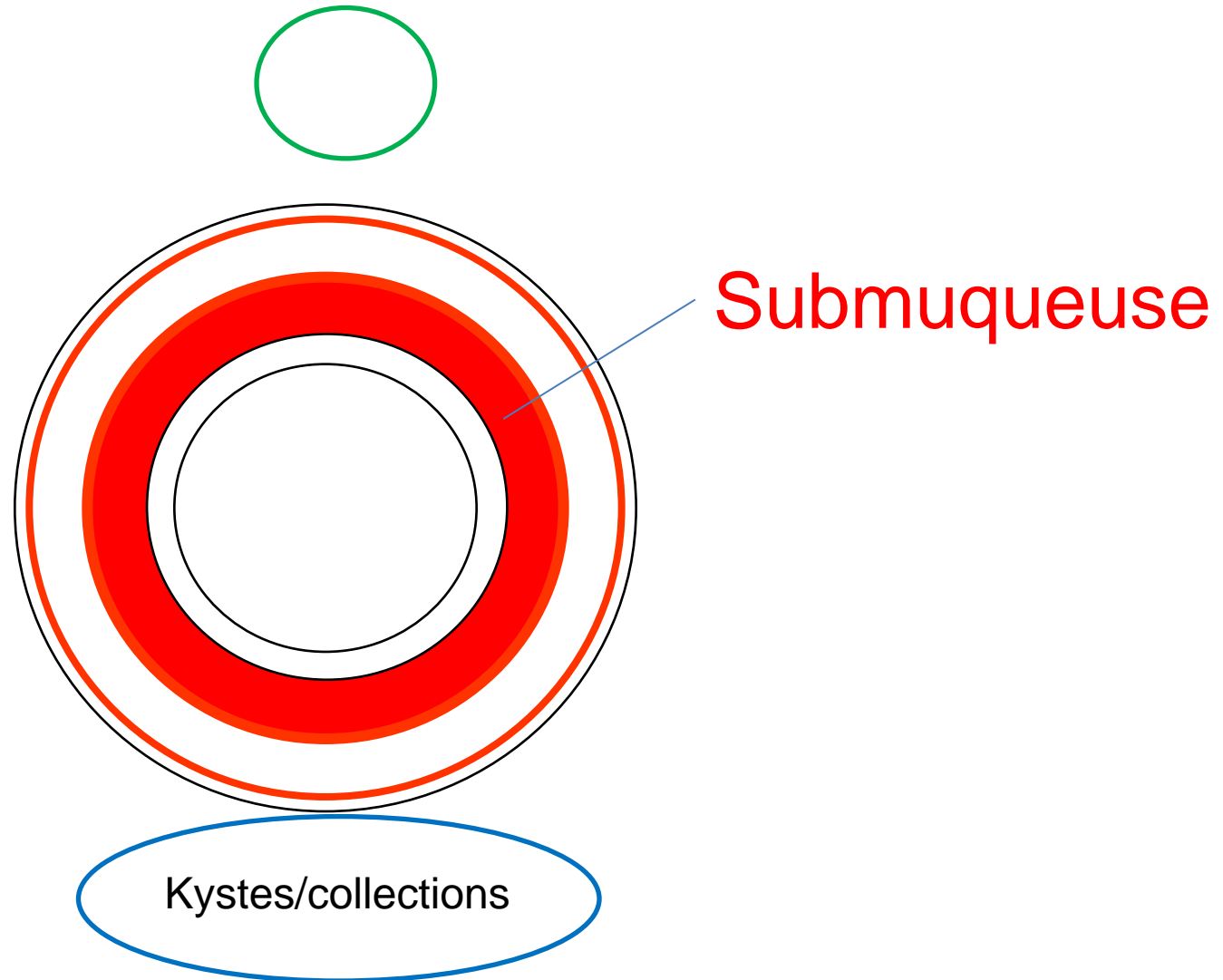
En:1 Ct:N



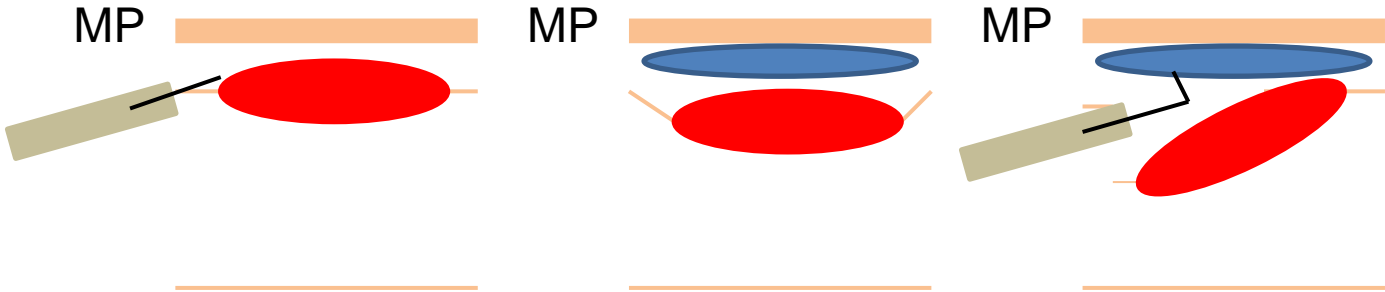
Physician :

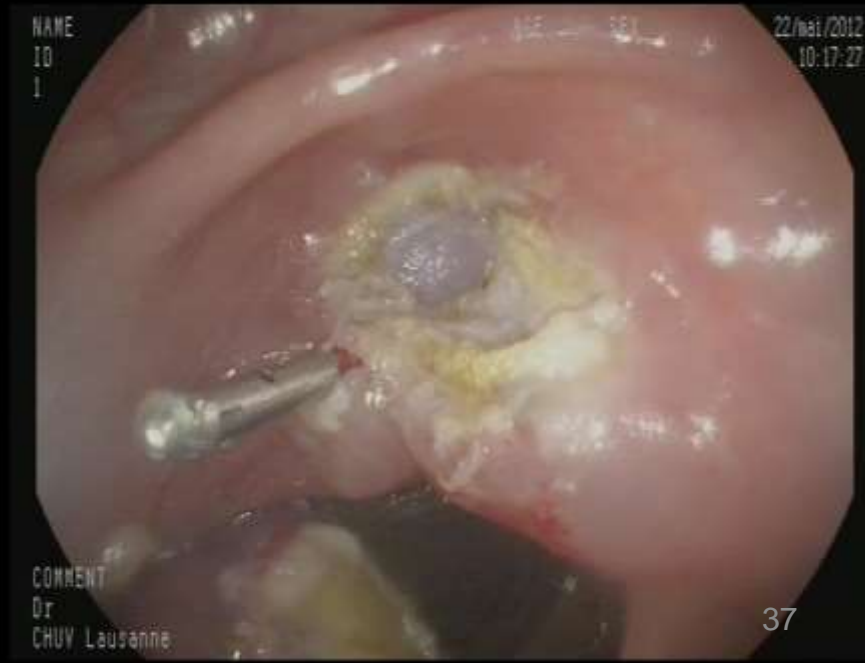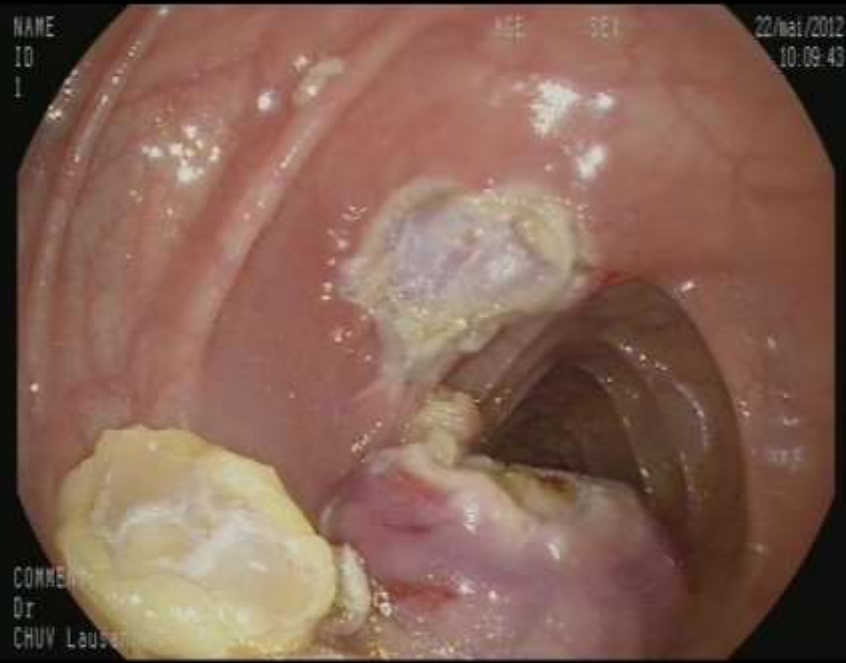
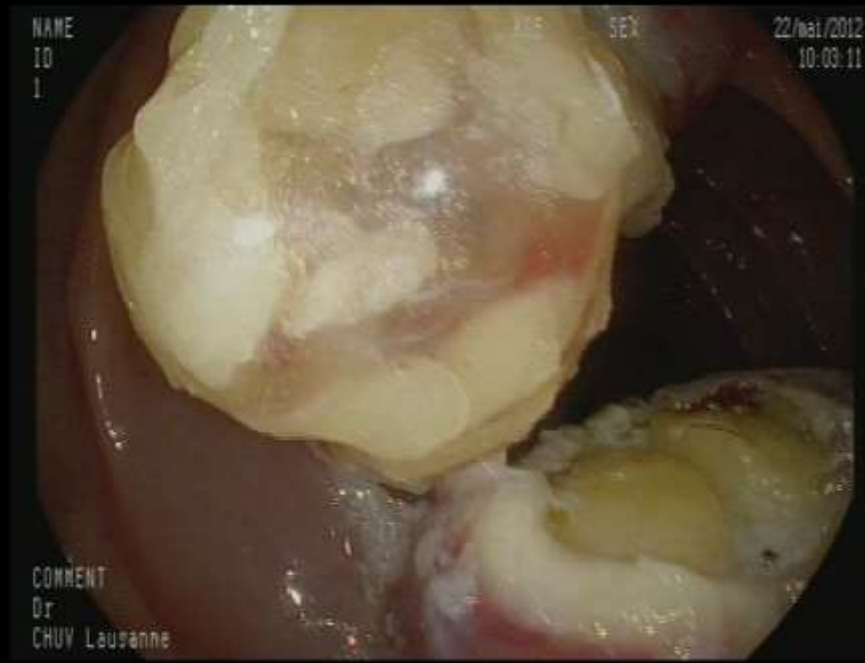
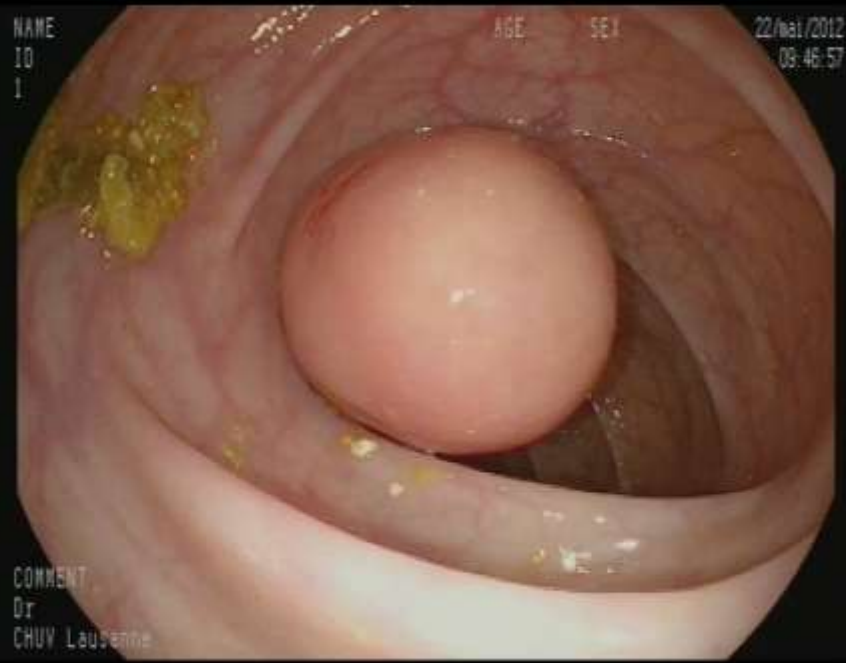Comment :

# Tractus digestif

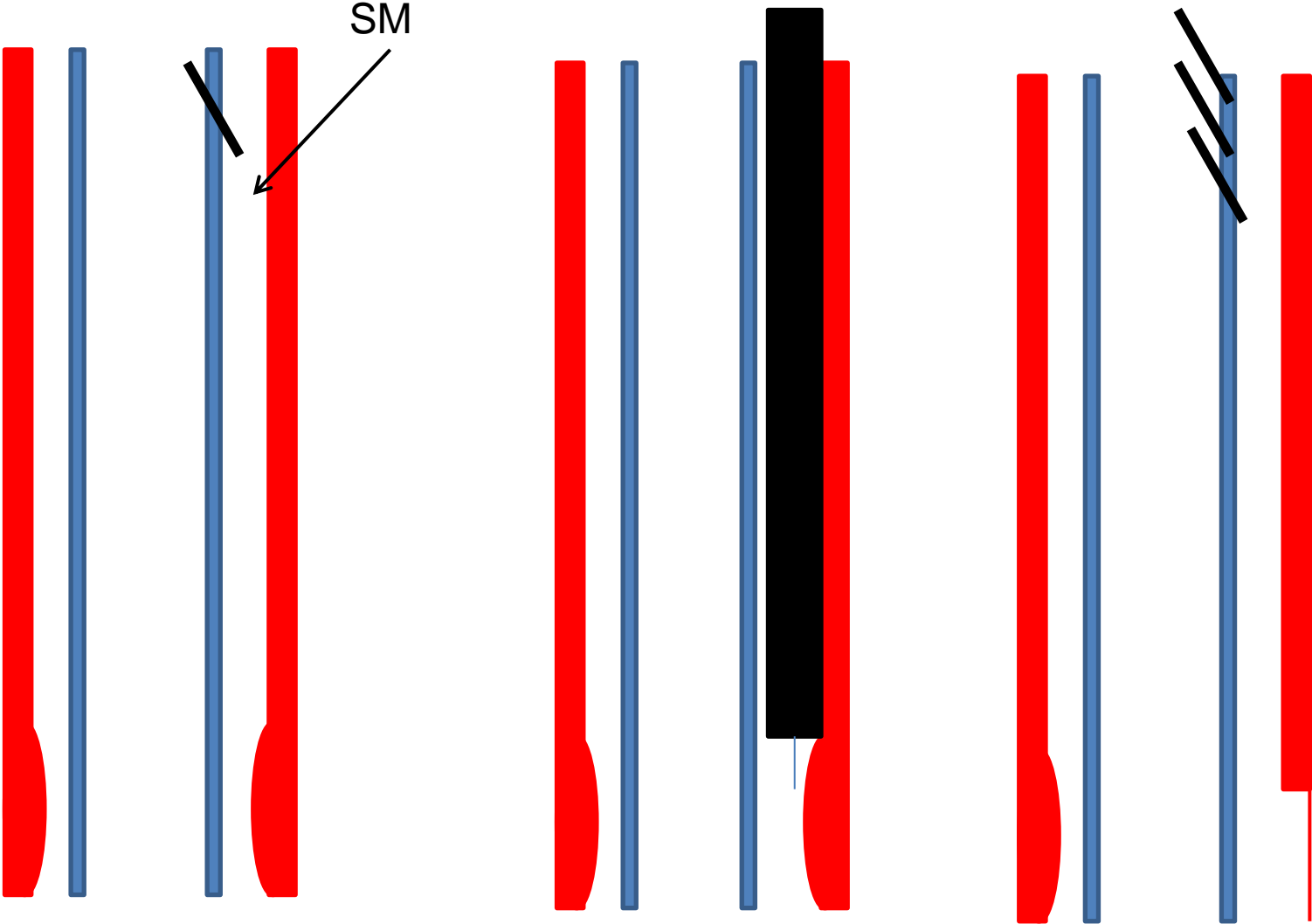


# Résection par la submuqueuse (ESD)

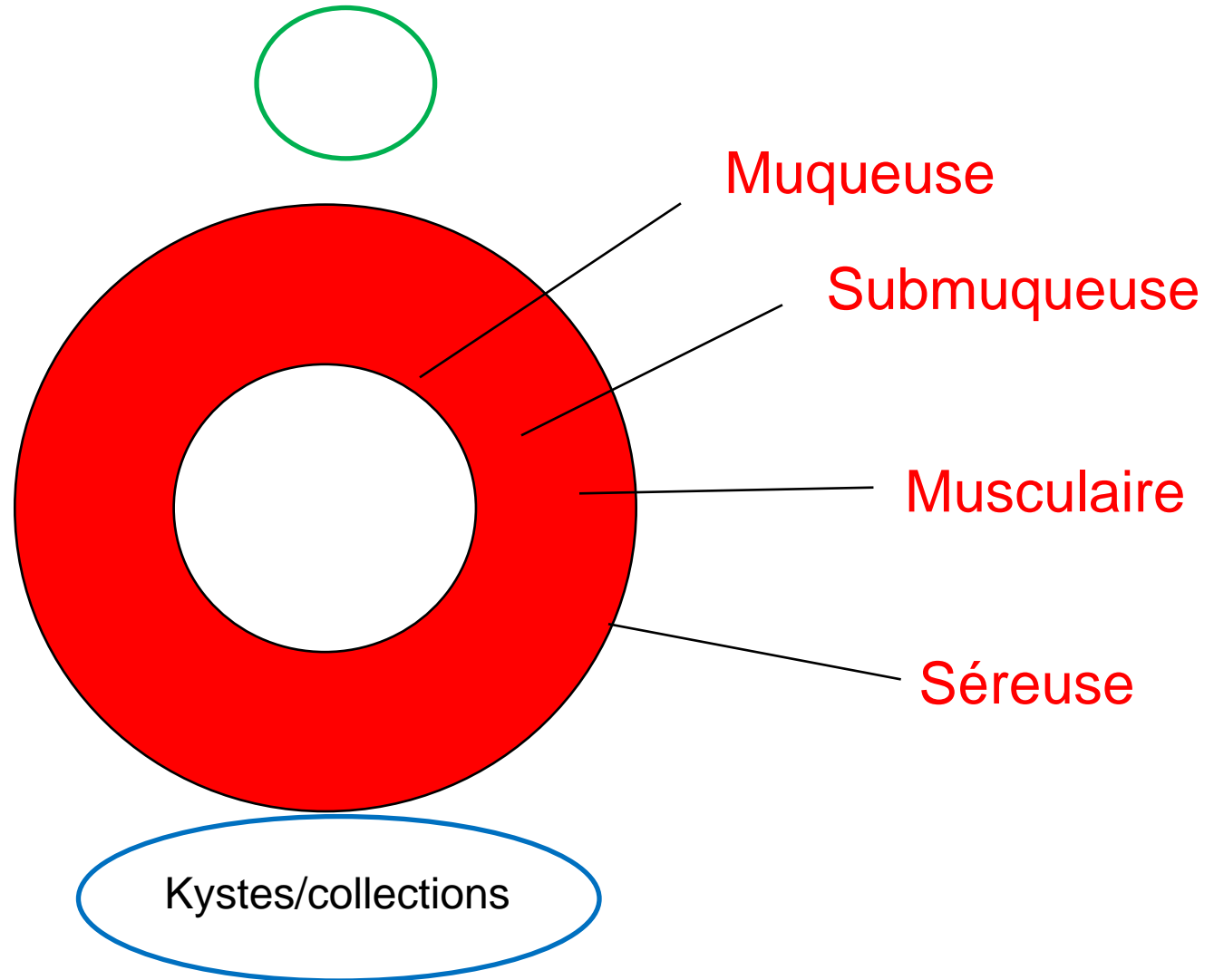




# POEM : Achalasie

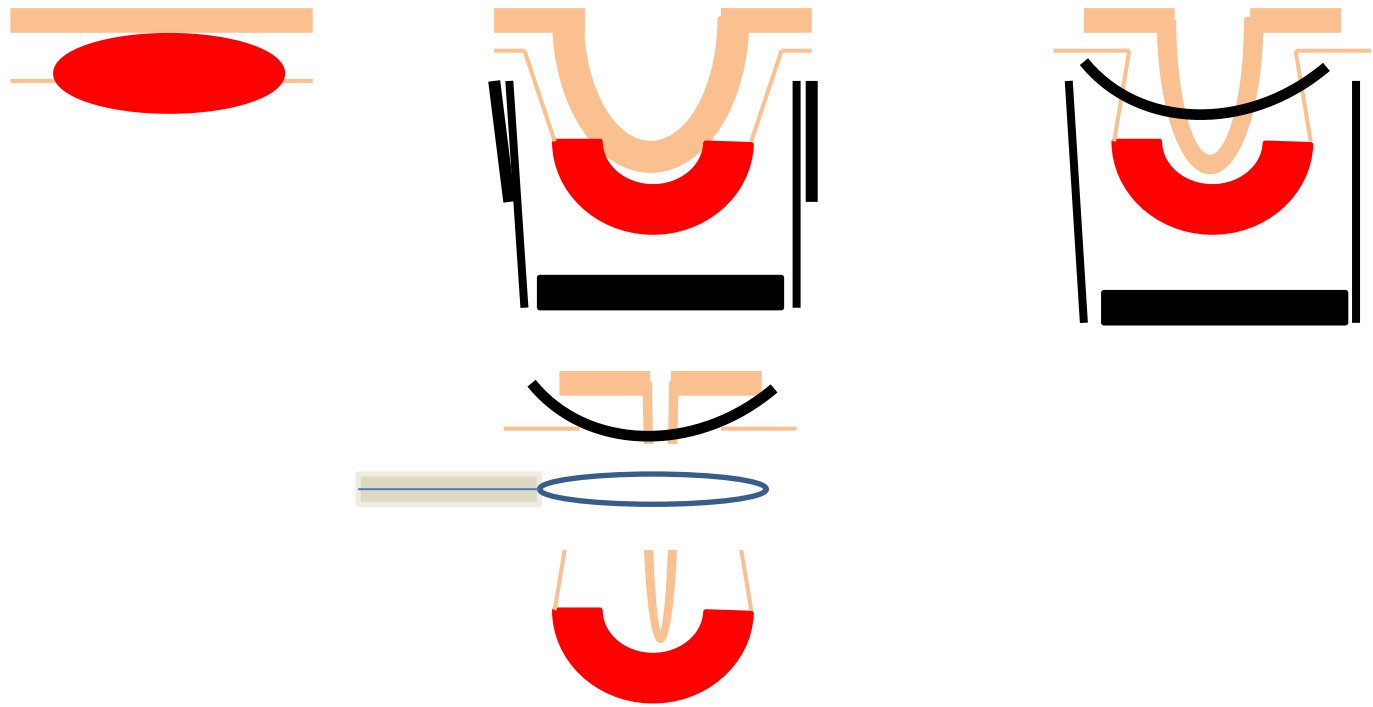


# Tractus digestif

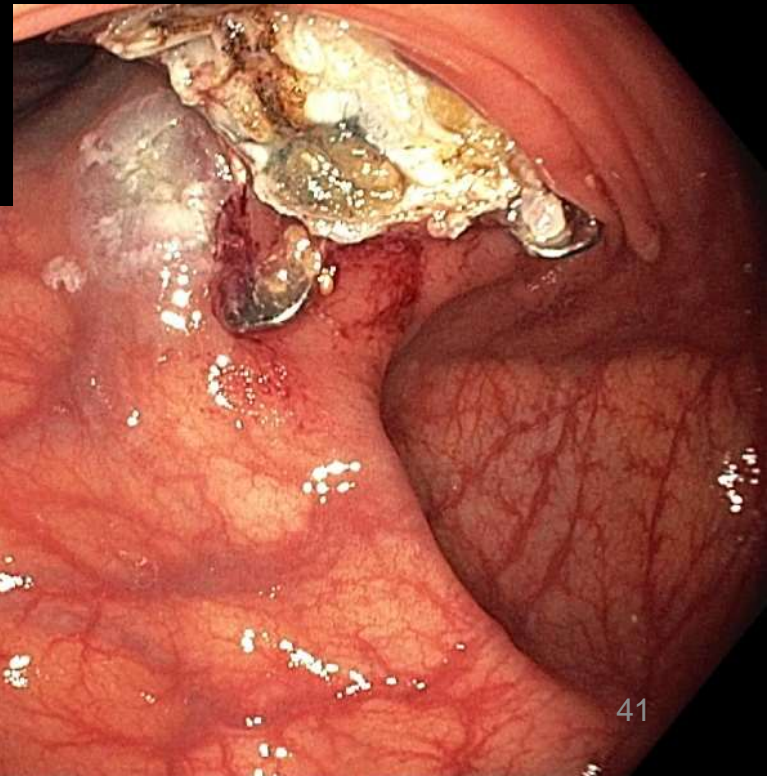
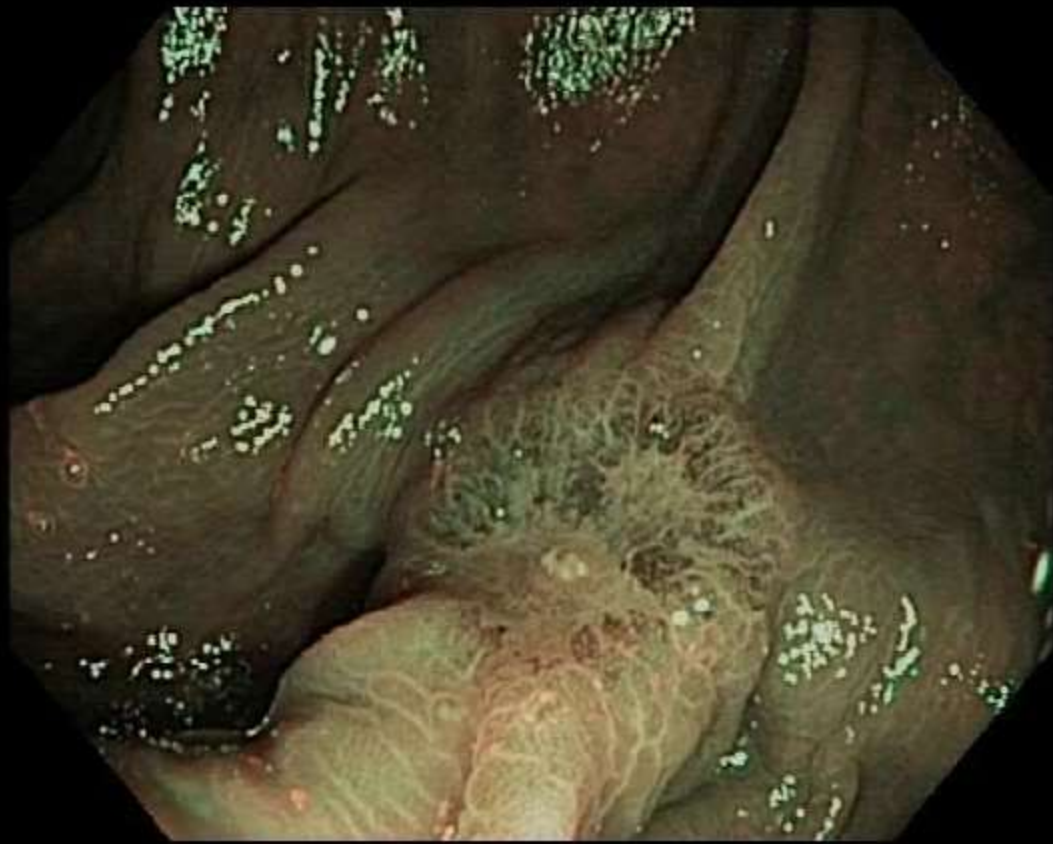

# Résection de la paroi

MP





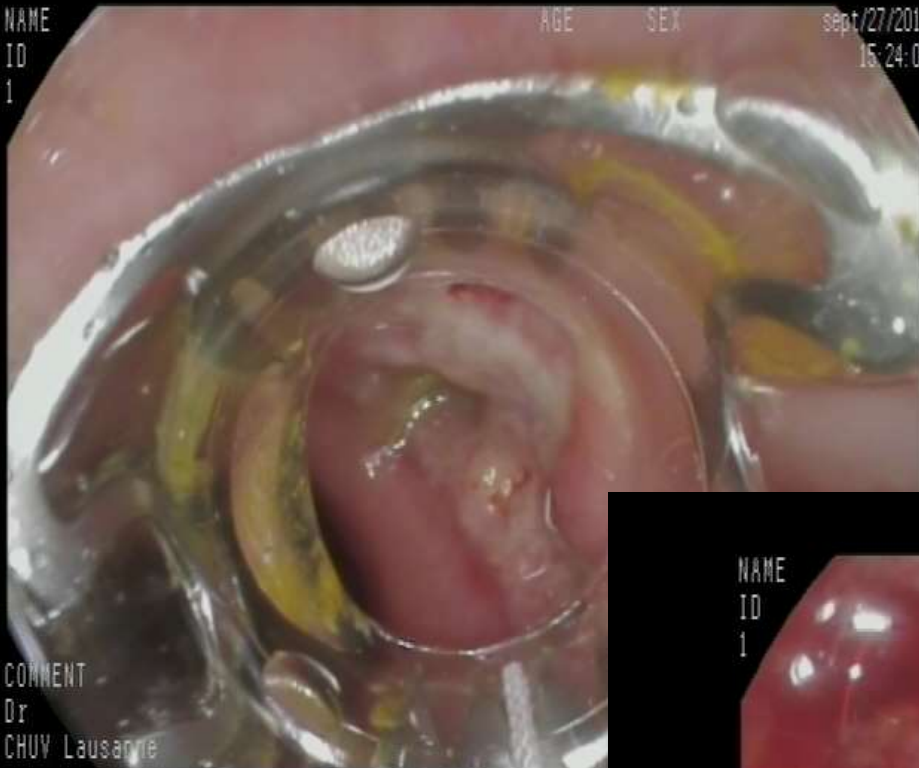

NAME  
ID  
1

AGE

SEX

sept/27/2013  
15:24:02



COMMENT  
Dr  
CHUV Lausanne

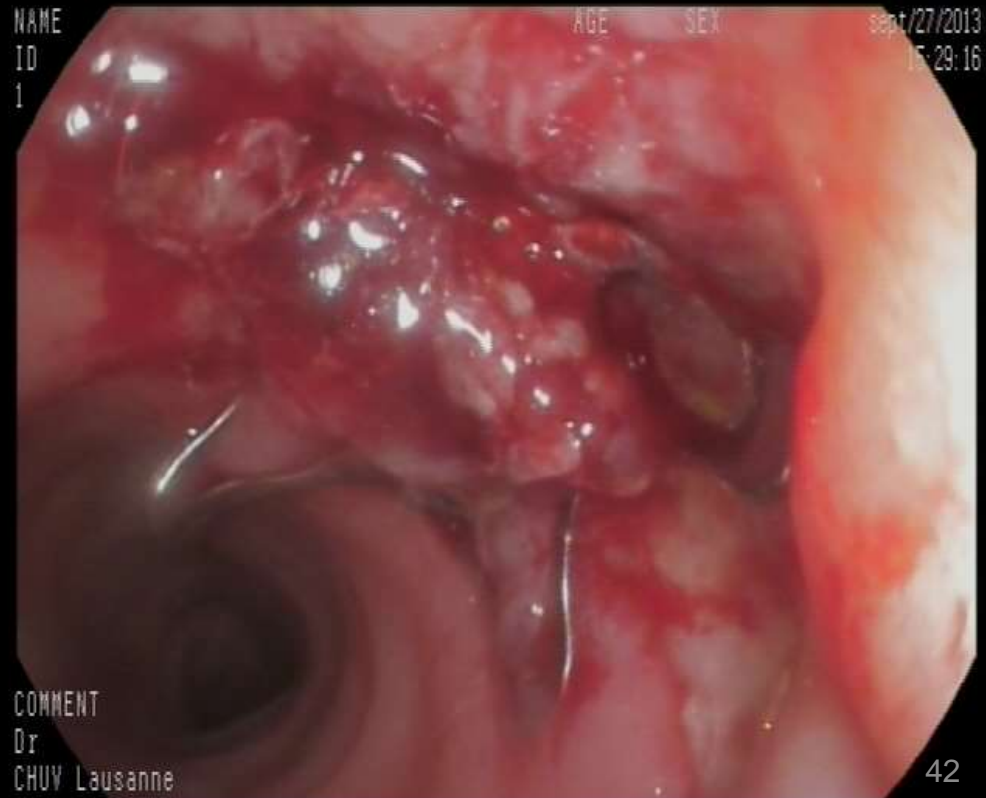
# Ttt fistule

NAME  
ID  
1

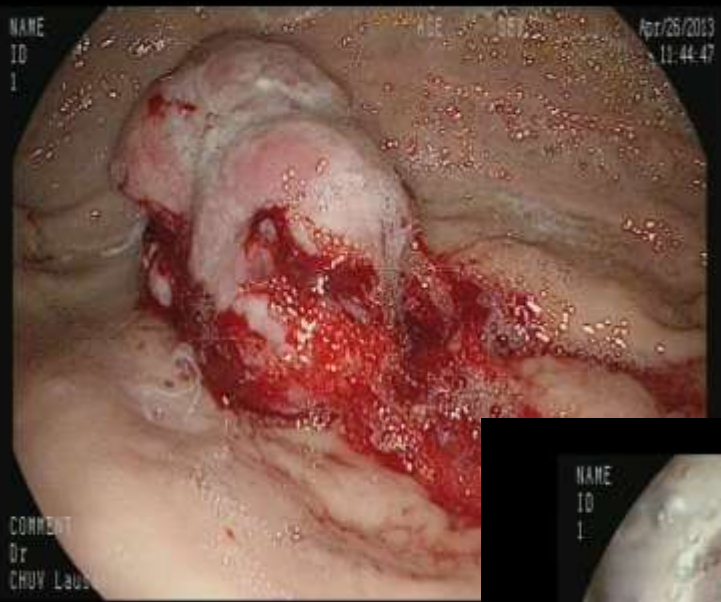
AGE

SEX

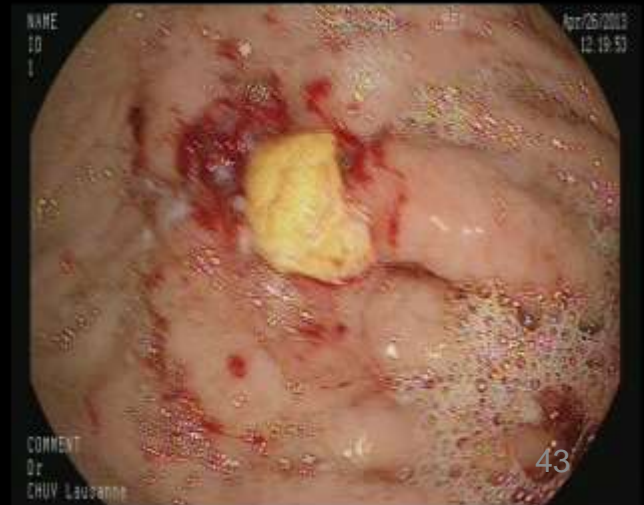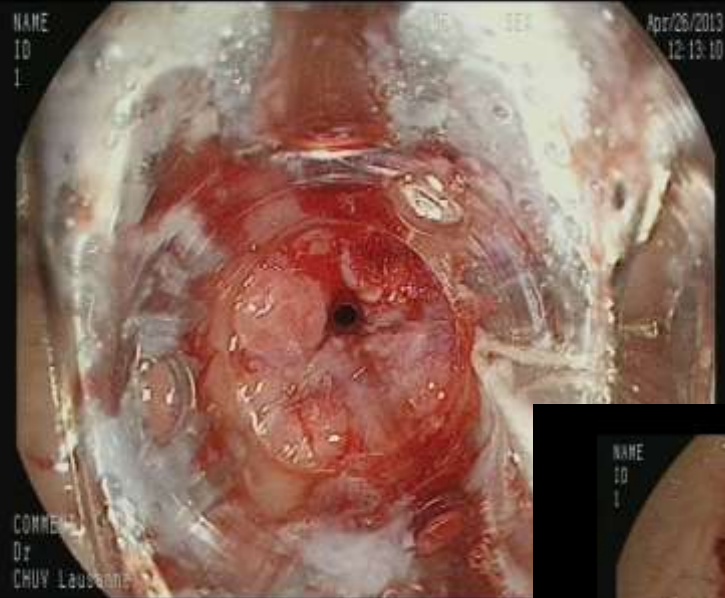
sept/27/2013  
15:29:16



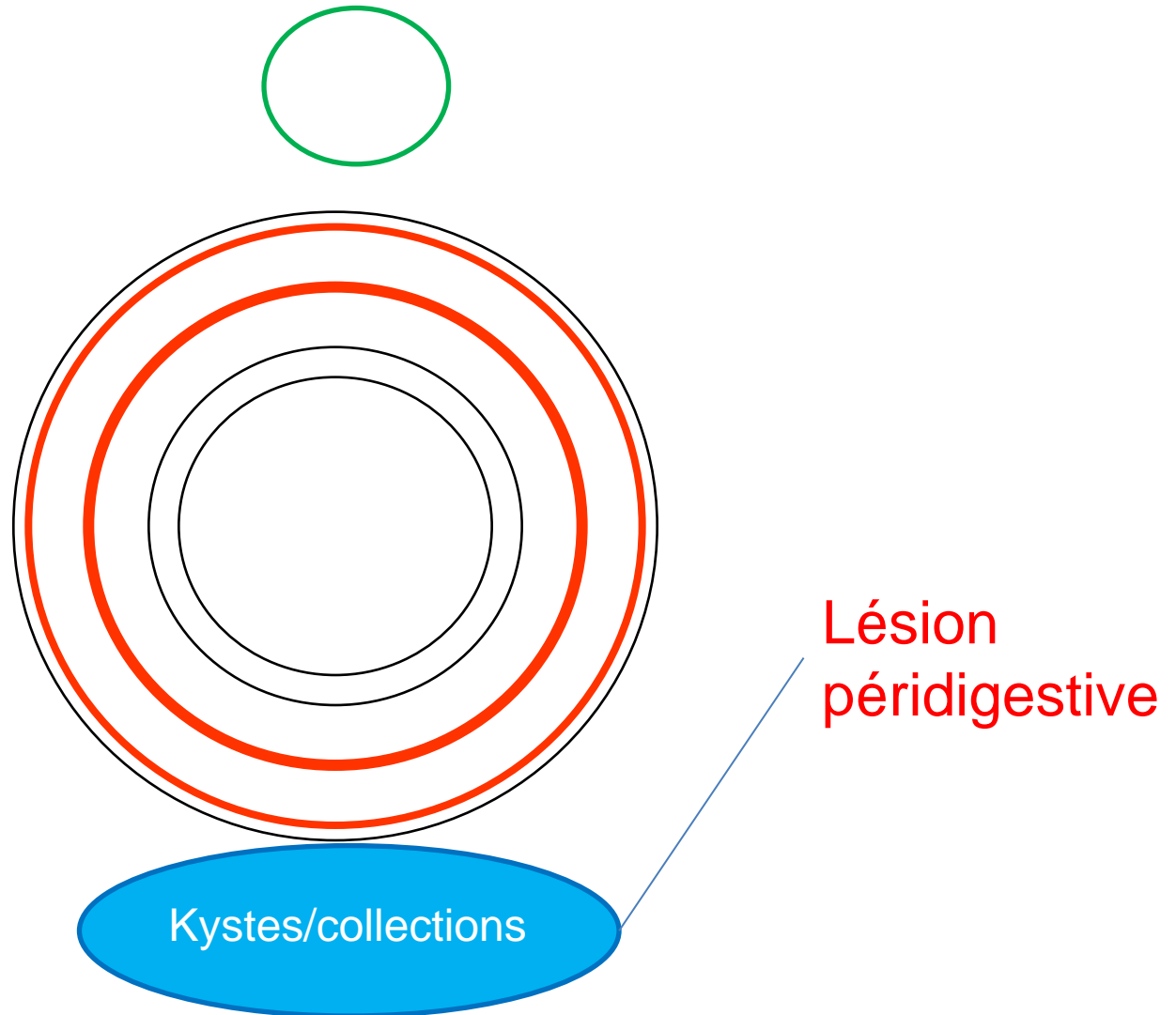
COMMENT  
Dr  
CHUV Lausanne

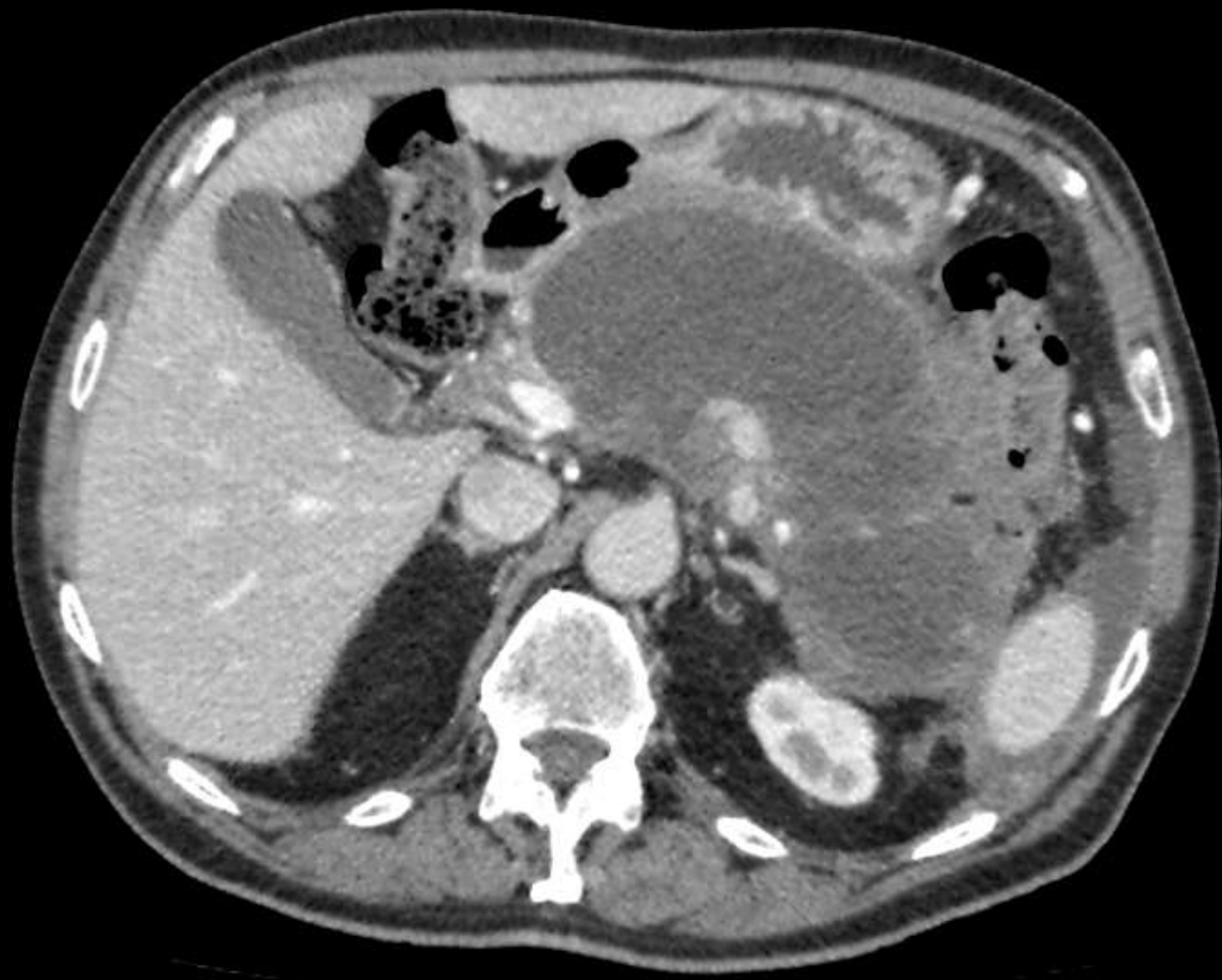

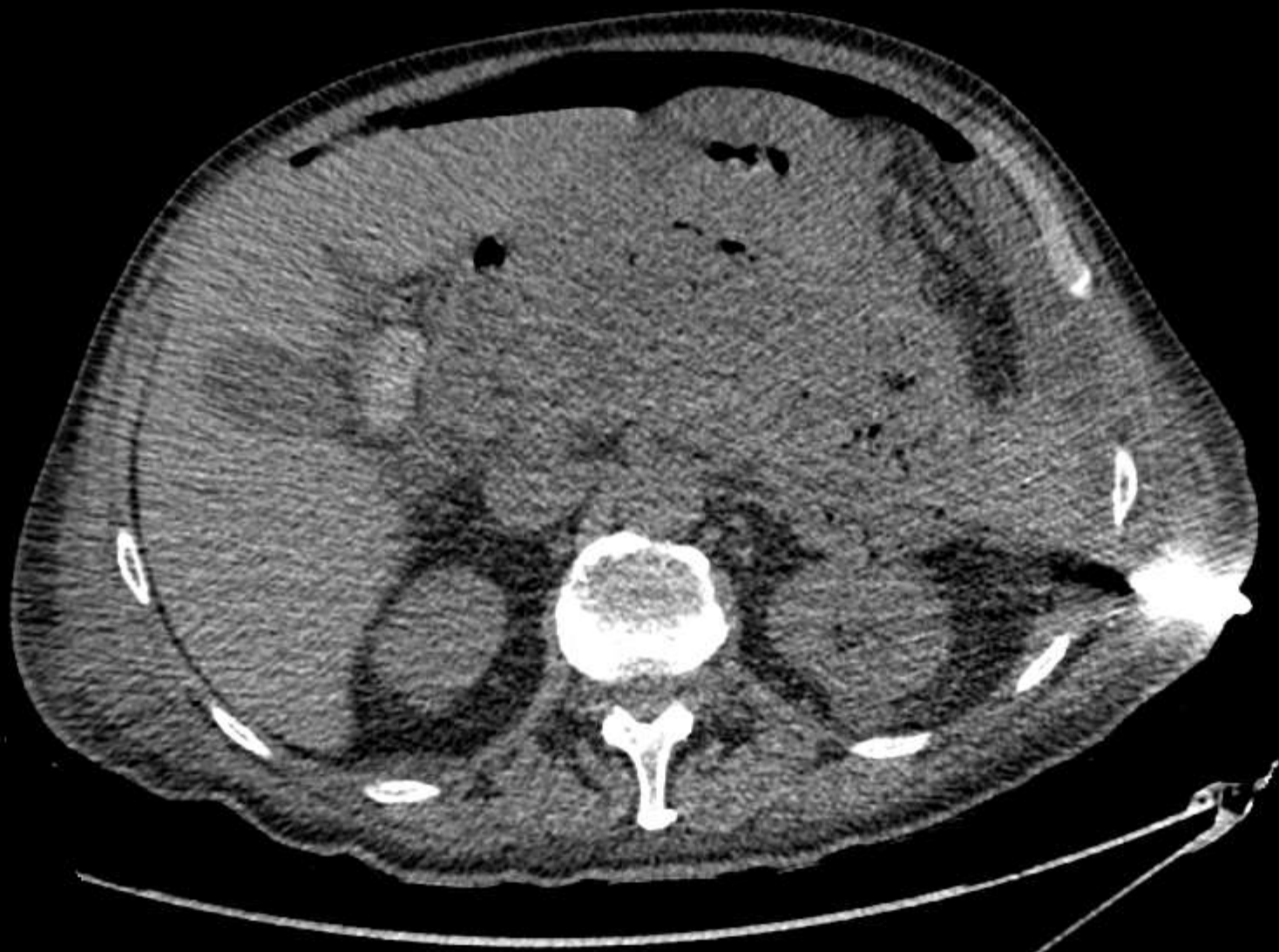Ttt perforation

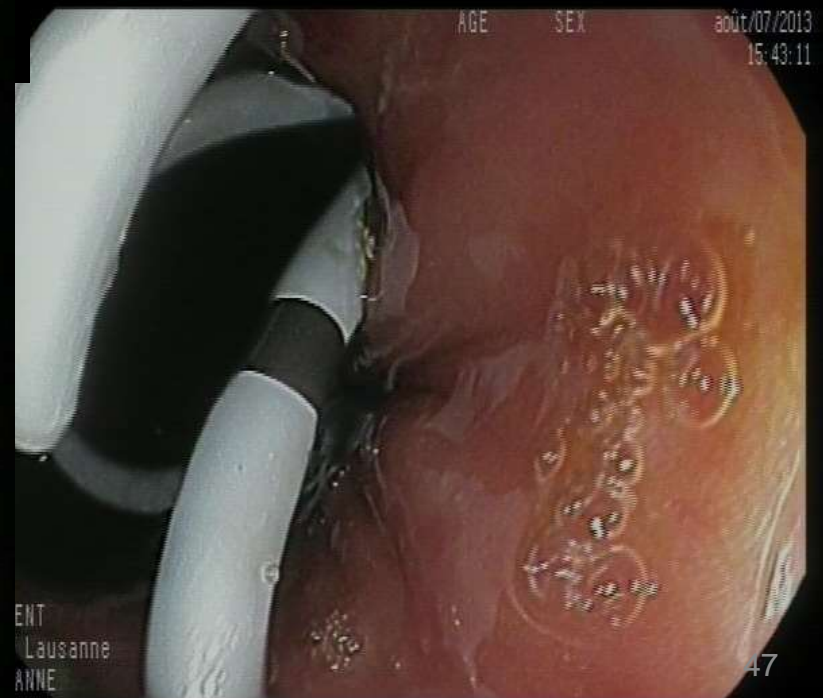
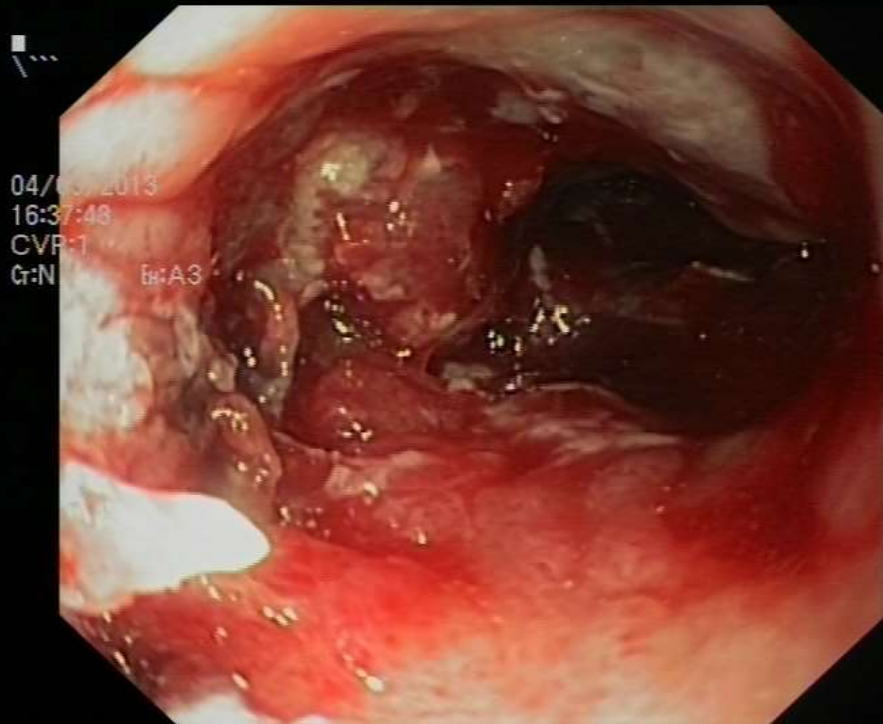
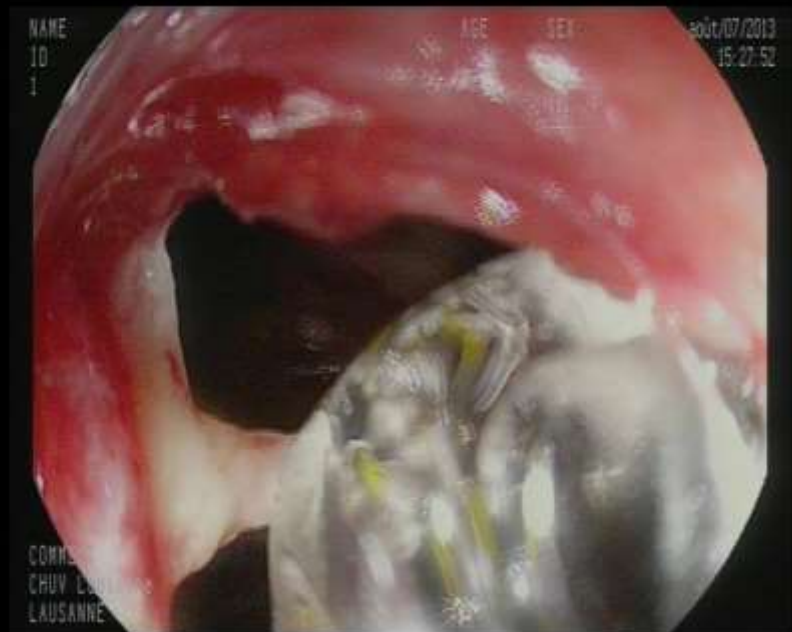
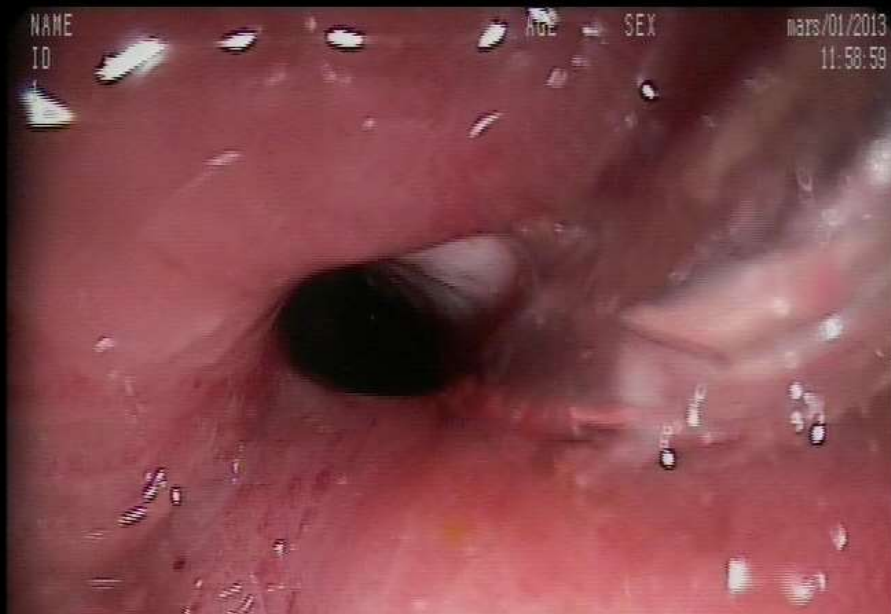

# Tractus digestif

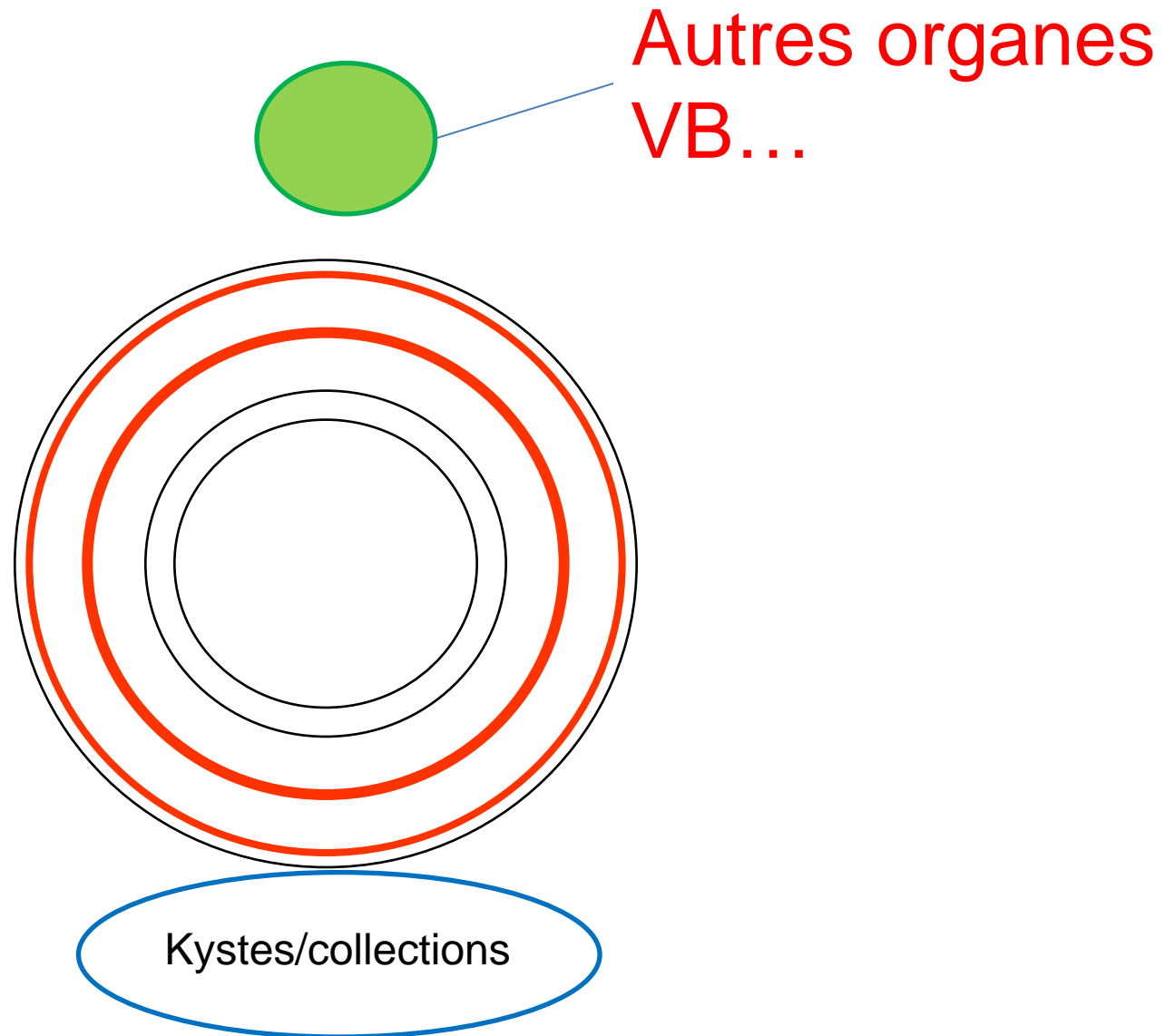






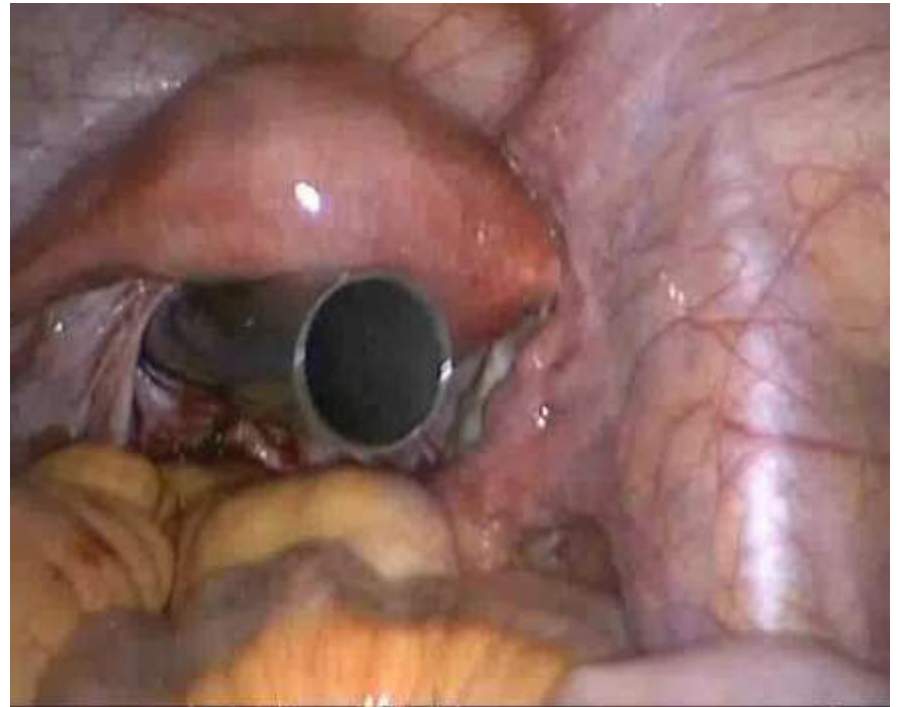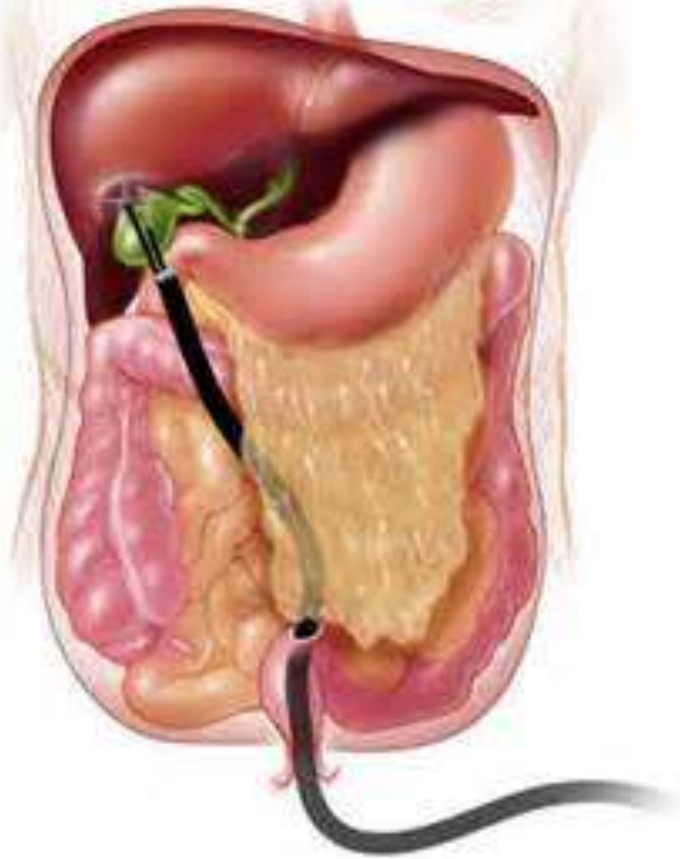


# Tractus digestif



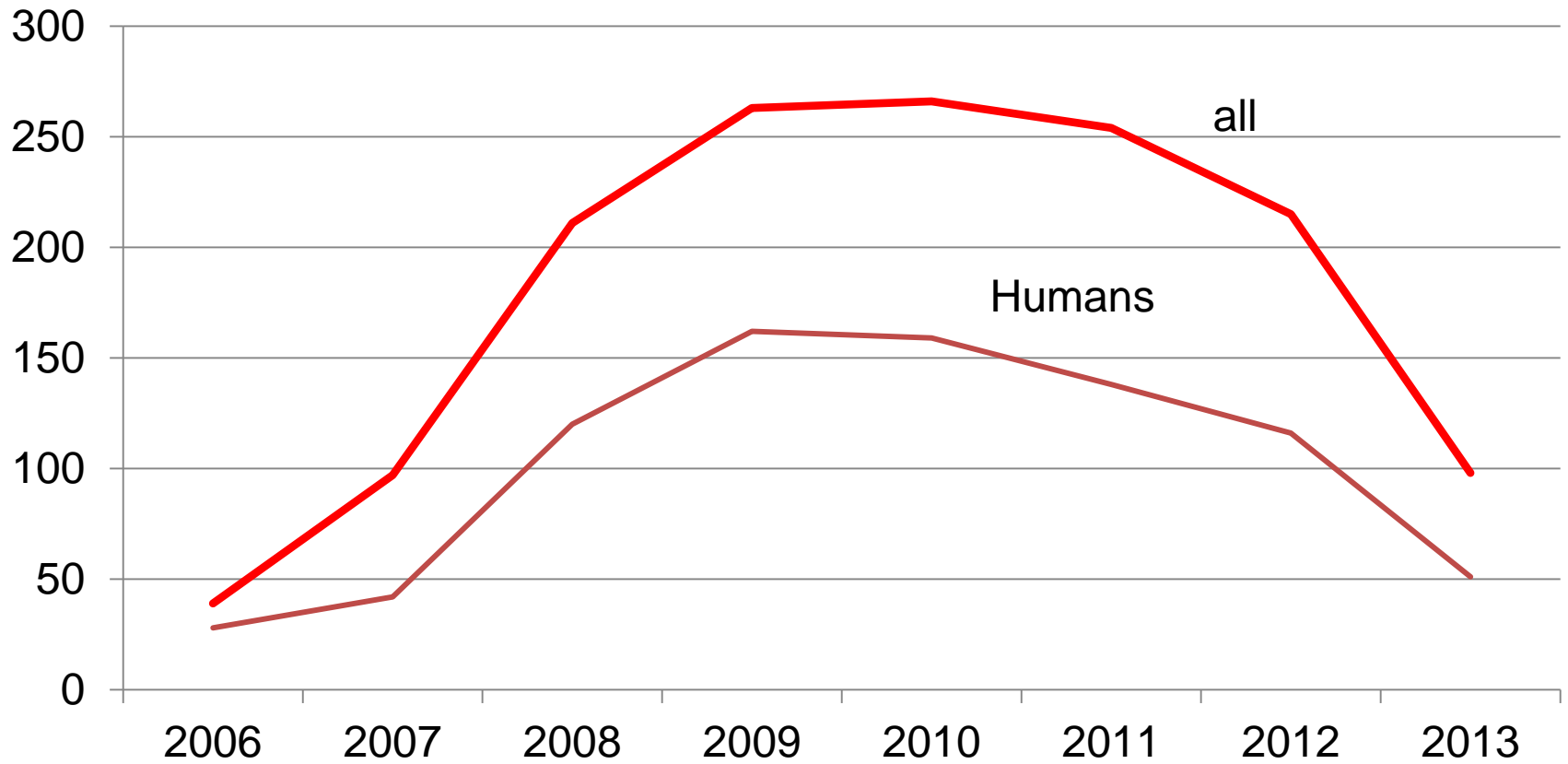


## Natural orifice transluminal endoscopic surgery

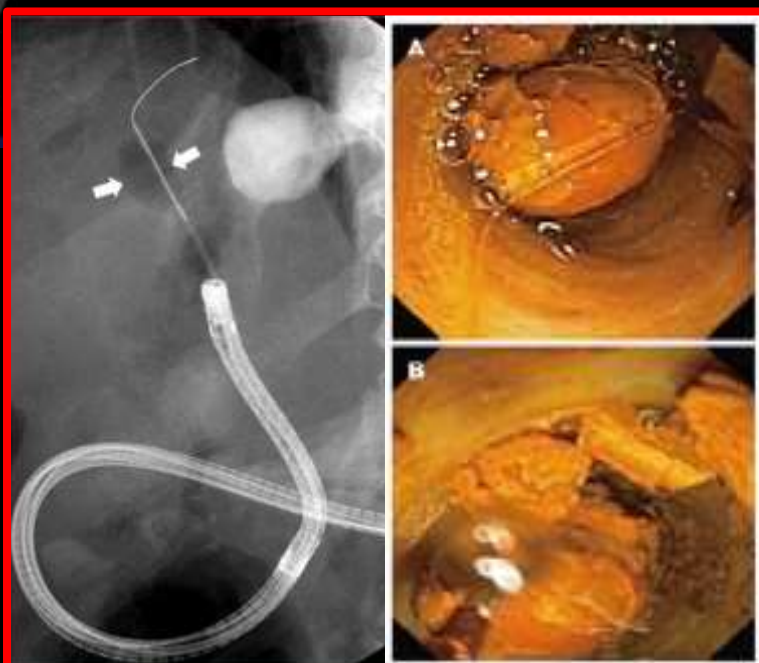
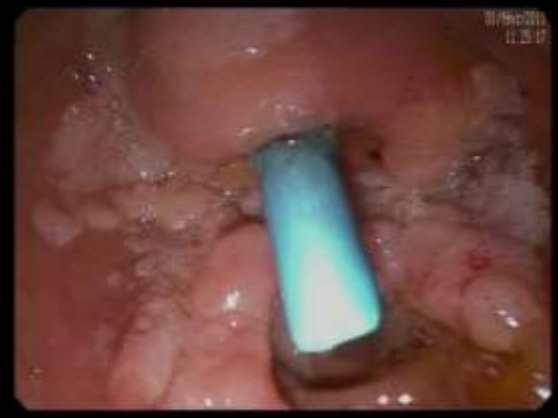
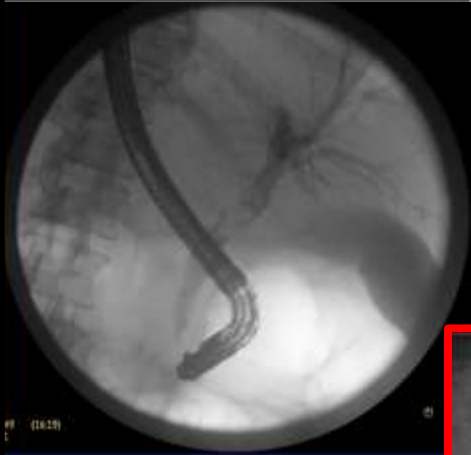
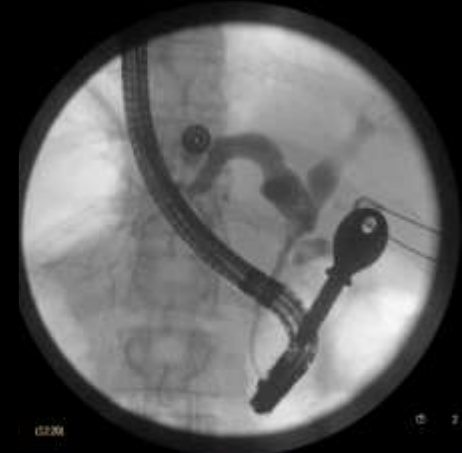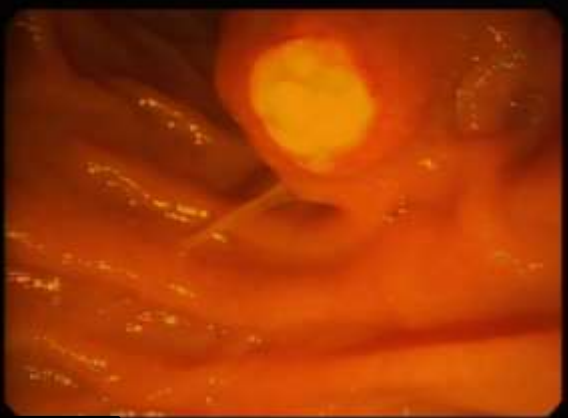# NOTES ?

# publications



# ERCP

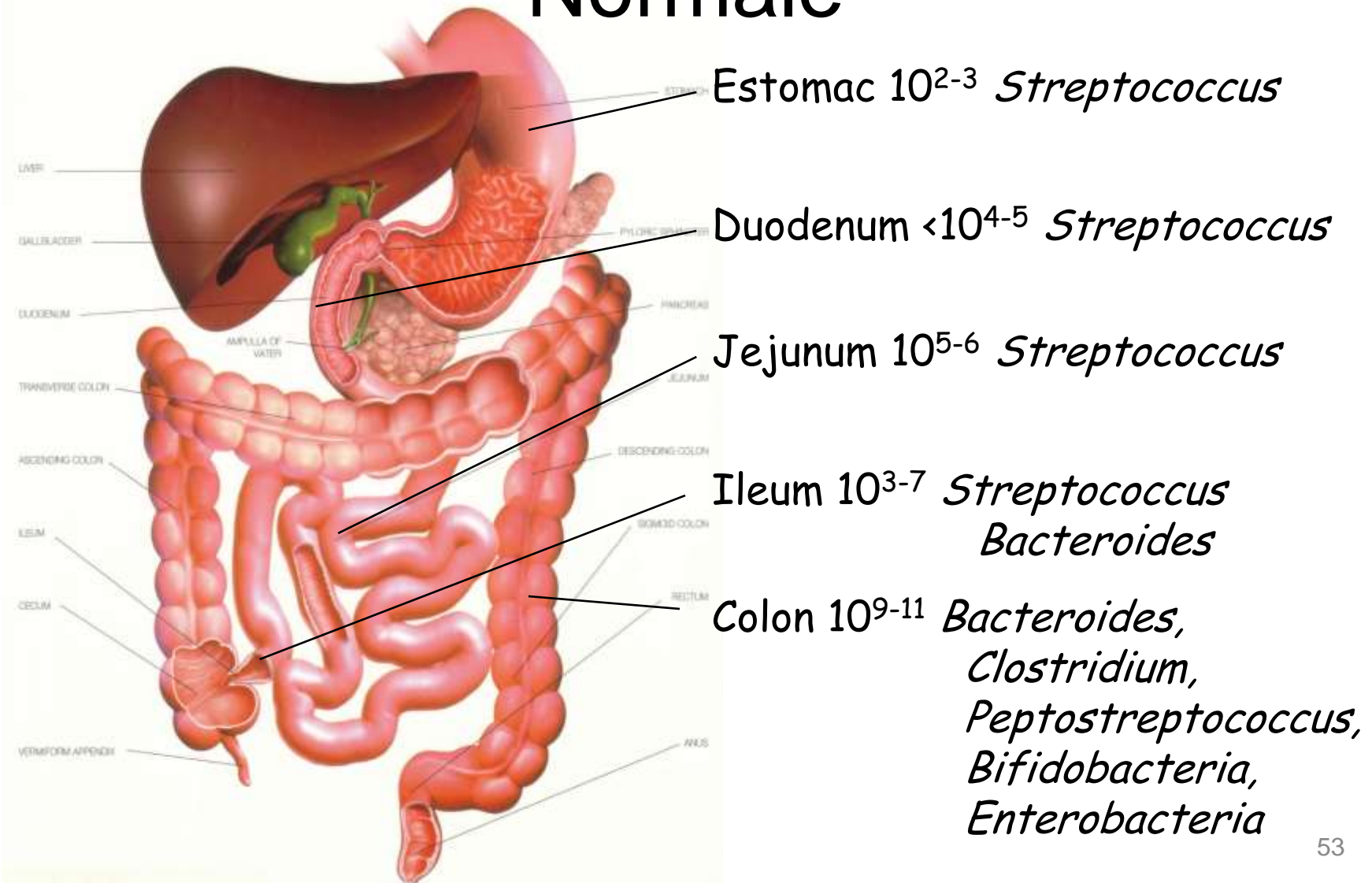


Biopsies ciblée  
Ttt lithiases (Laser)

# Hygiène et endoscopie digestive

- Milieu de travail: toujours contaminé (flore intestinale)
- Travail entre les microbes
- Prophylaxie antibiotique:
  - Drainage incomplet
  - Ponction lésions kystiques
  - Implantation de prothèses biliaires
- Prophylaxie de l'endocardite
- Endoscopie peri-opératoire: instruments stériles!

# Flore Gastro-intestinale Normale



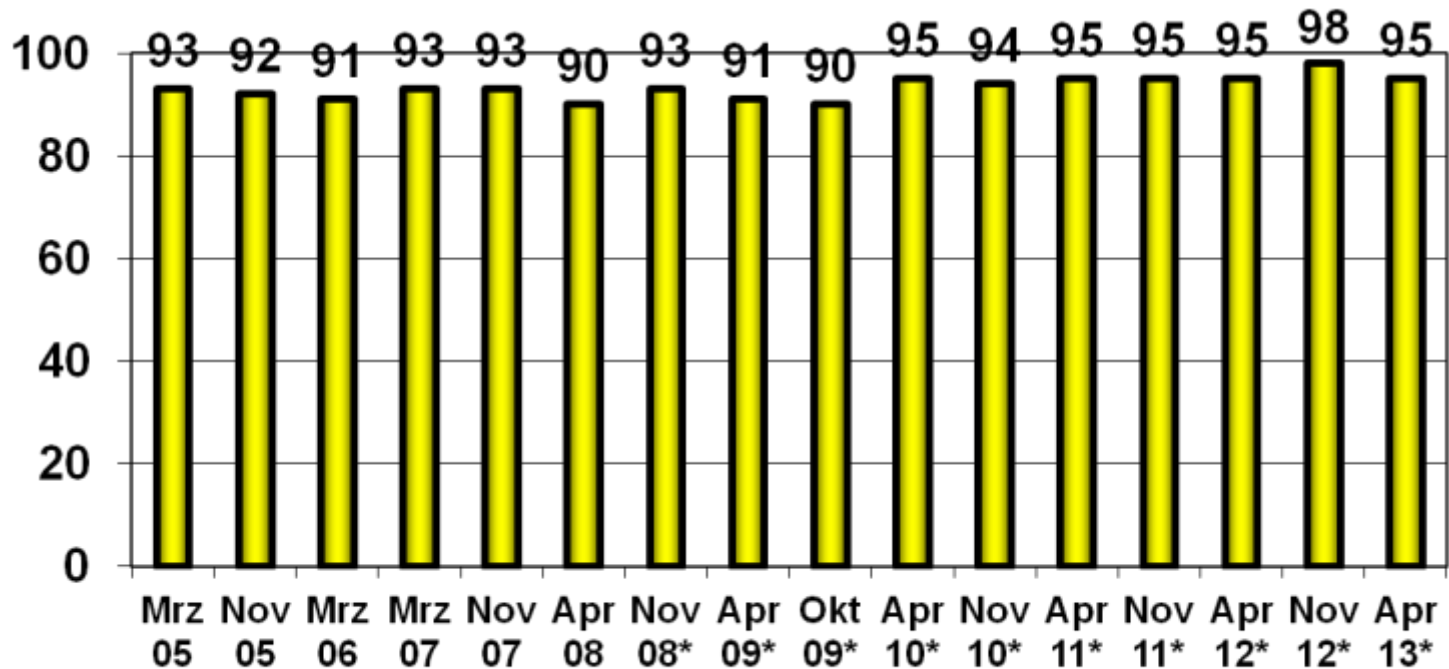
# Hygiène et endoscopie digestive

- Milieu de travail: toujours contaminé (flore intestinale)
- Travail entre les microbes
- Prophylaxie antibiotique:
  - Drainage incomplet
  - Ponction lésions kystiques
  - Implantation de prothèses biliaires
- Prophylaxie de l'endocardite
- Endoscopie peri-opératoire: instruments stériles!

# Hygiène et endoscopie digestive

- But principal:
  - Éviter de transmettre des maladies infectieuses:
    - Hépatites
    - HIV
    - Bactéries problématiques: MRSA etc.

# Endoscopes propres (%)



\* inkl. nicht Bact Lab Tests

Schweizerische Gesellschaft für Gastroenterologie

Société Suisse de Gastroentérologie

Società Svizzera di Gastroenterologia





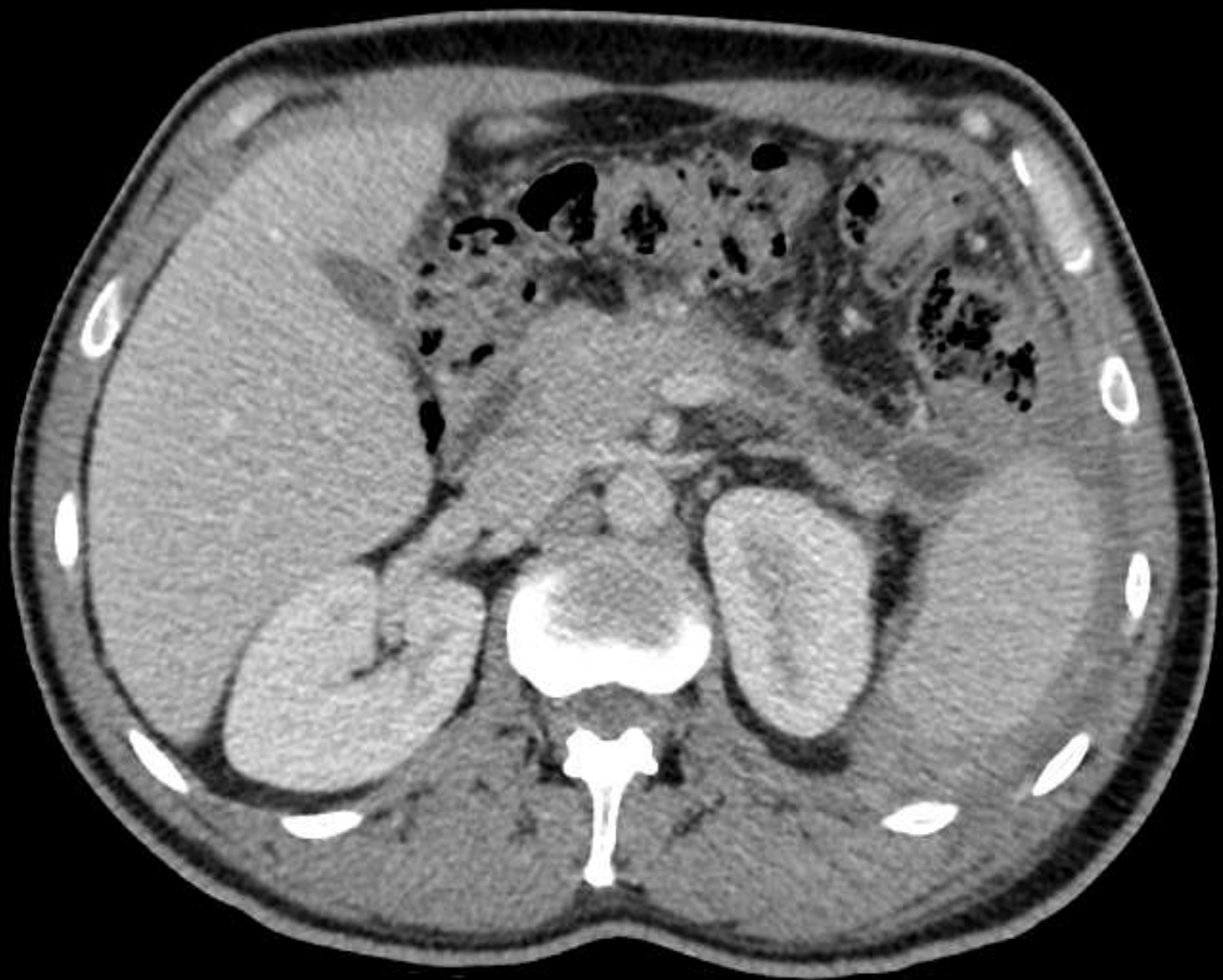# Conclusion:

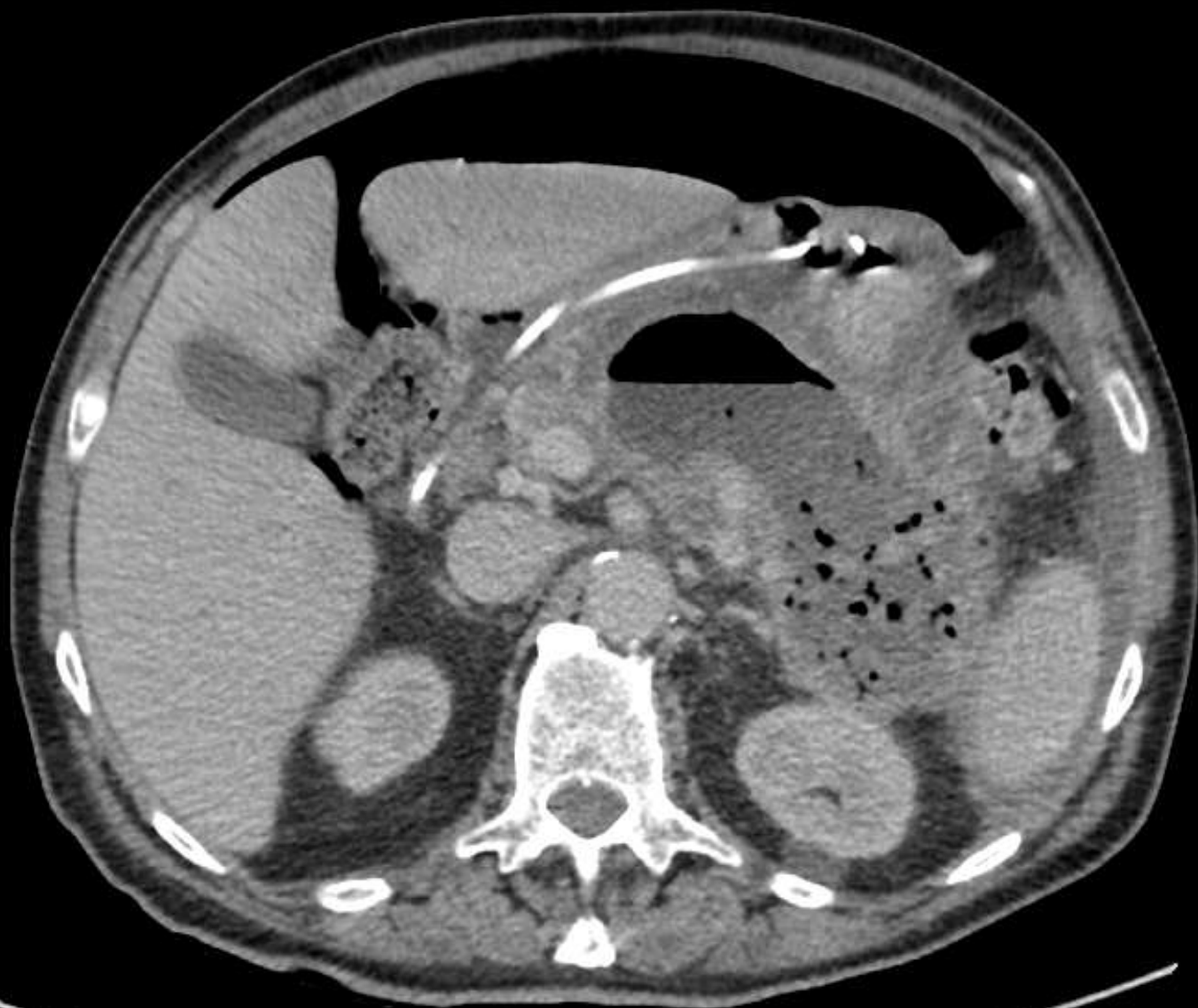- Développement en endoscopie:
  - Les limites ne sont pas encore connues
  - Le développement s'est ralenti
  - Progression pas à pas
  - Les exigences hygiéniques restent les mêmes: éviter de transmettre des maladies infectieuses

**That's all,  
folks!**



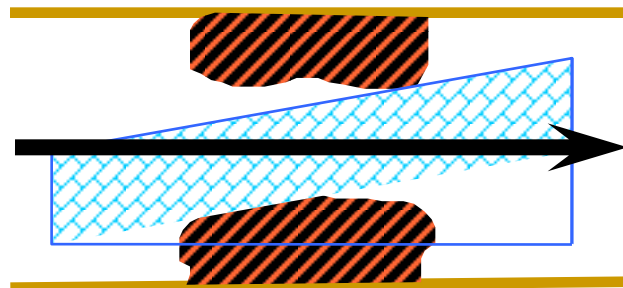
FIN





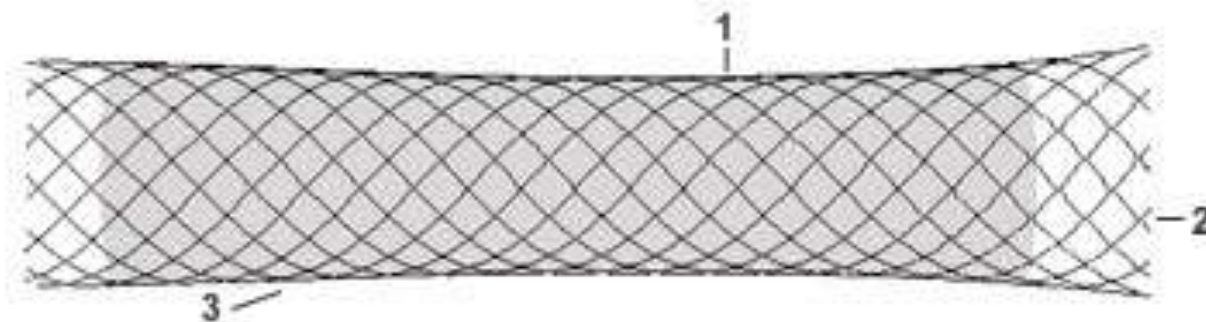
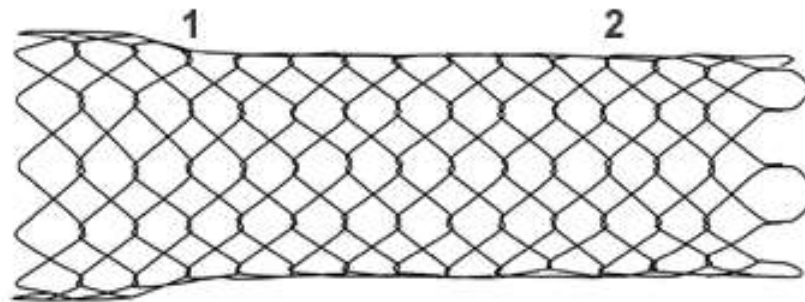
# Effets des endoprothèses

- Rétablissement du transit
- Certains effets sur l'hémorragie (compression)

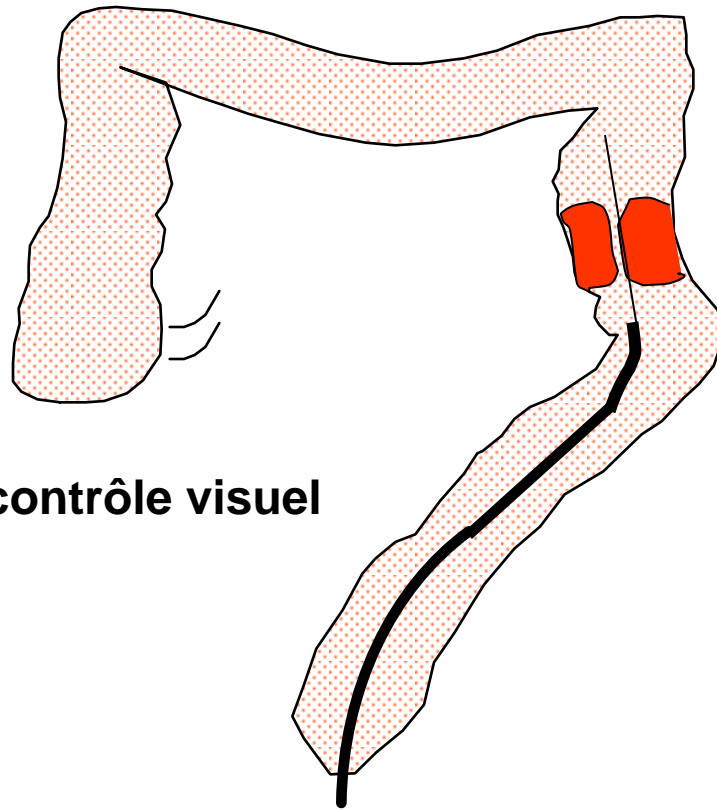


transit

# Les prothèses



# Technique

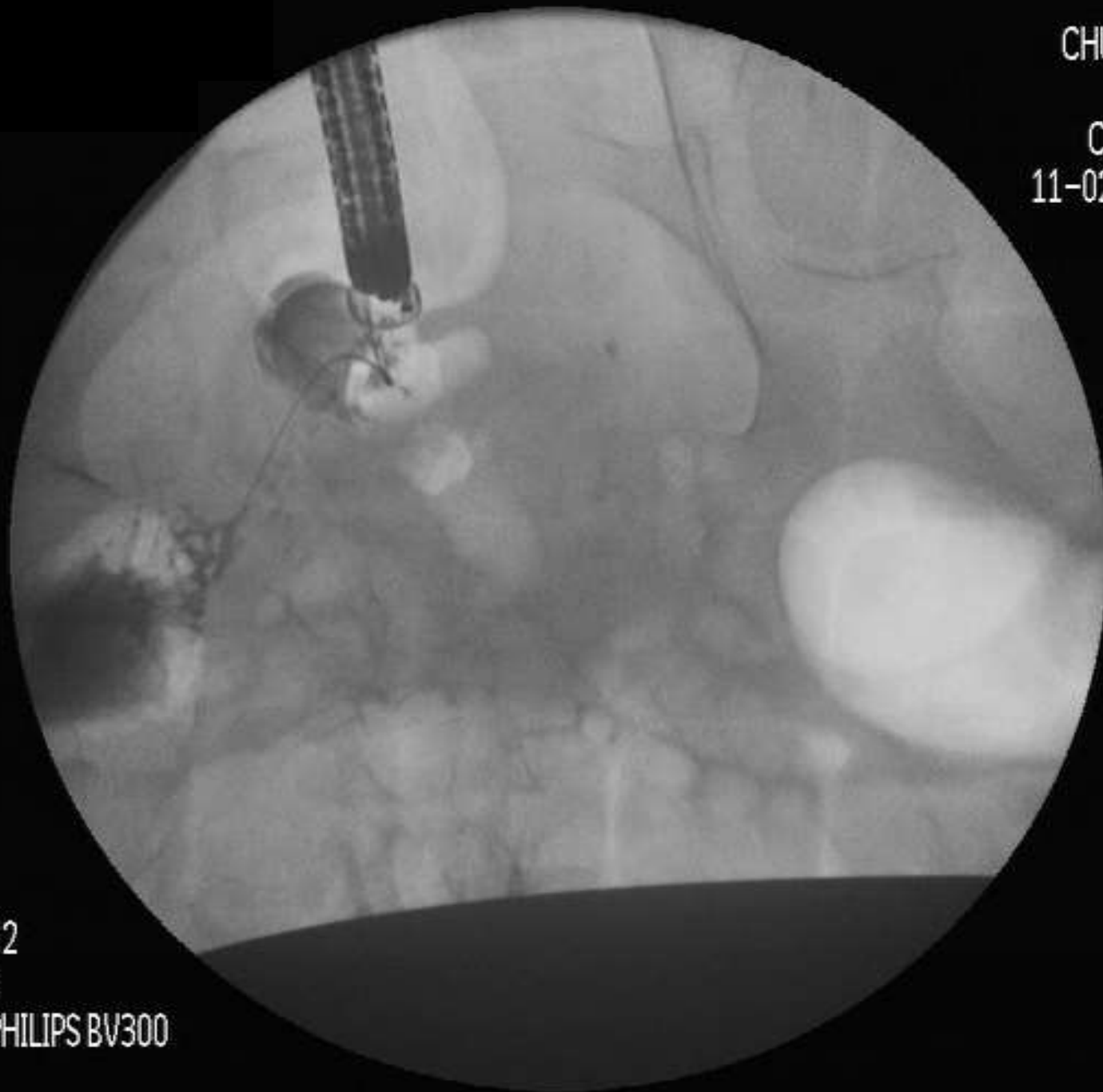


Mise en place sous contrôle visuel

Dilatation éventuelle  
< 12 mm



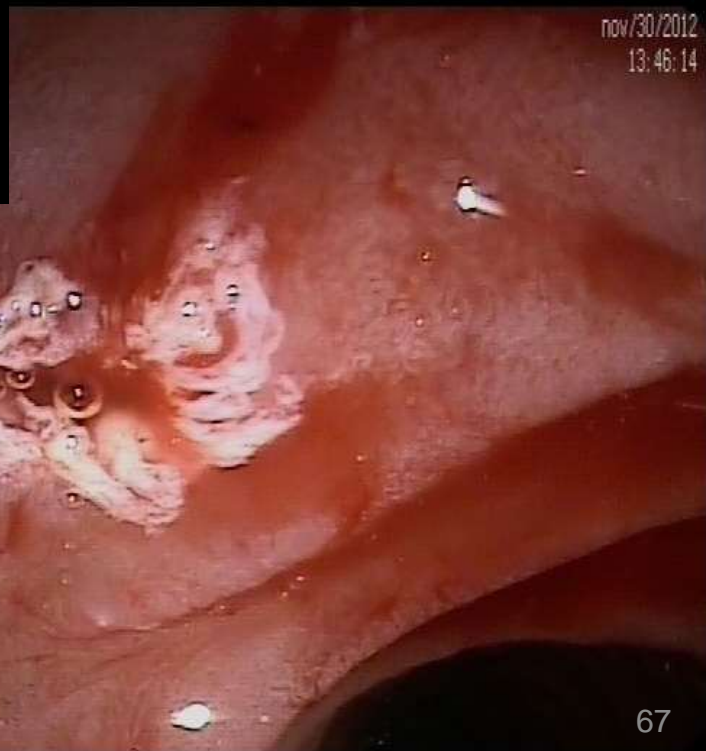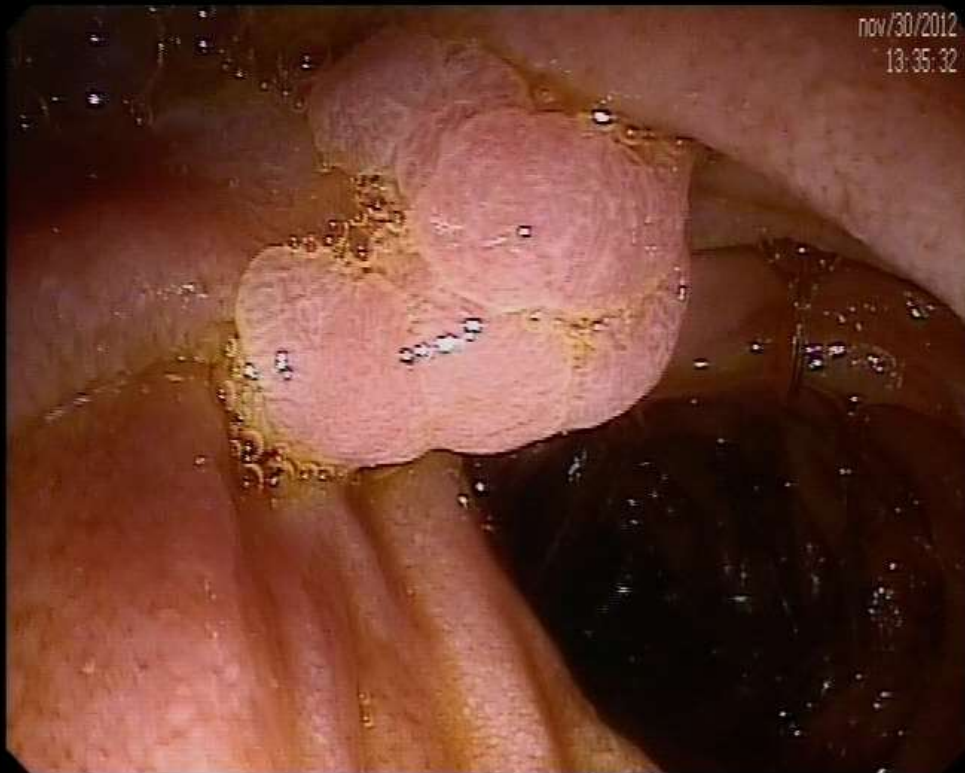CHUV - Lausanne  
DORTA GIAN  
COLONOSCOPIE  
11-02-2004 15:57



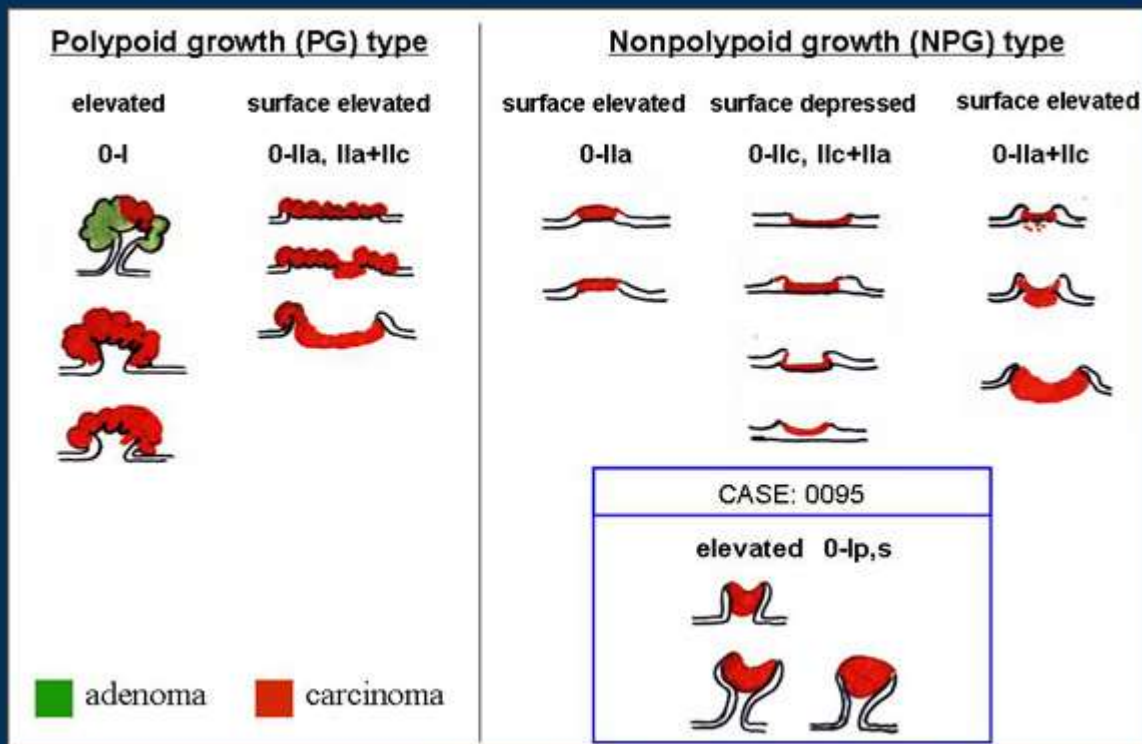
12  
1  
PHILIPS BV300

CHUV - Lausanne  
DORTA GIAN  
COLONOSCOPIE  
11-02-2004 16:07

25  
1  
PHILIPS BV300



**Fig 1. Morphological features of colorectal carcinoma**



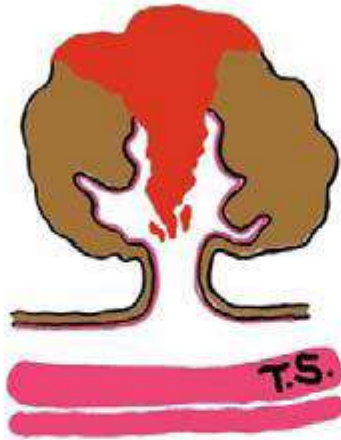
(Adapted from Shimoda T et al. Cancer 64:1138-46, 1989)

# Côlon: Haggitt classification



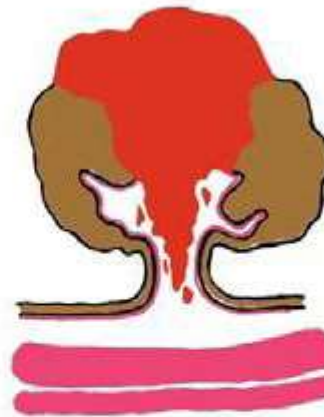Level 1:  
invasion of the  
submucosa but  
limited to the head  
of the polyp

N = 0%



Level 2:  
invasion extending  
into the neck of  
polyp

N = 0%



Level 3:  
invasion into any  
part of the stalk

N = 10%

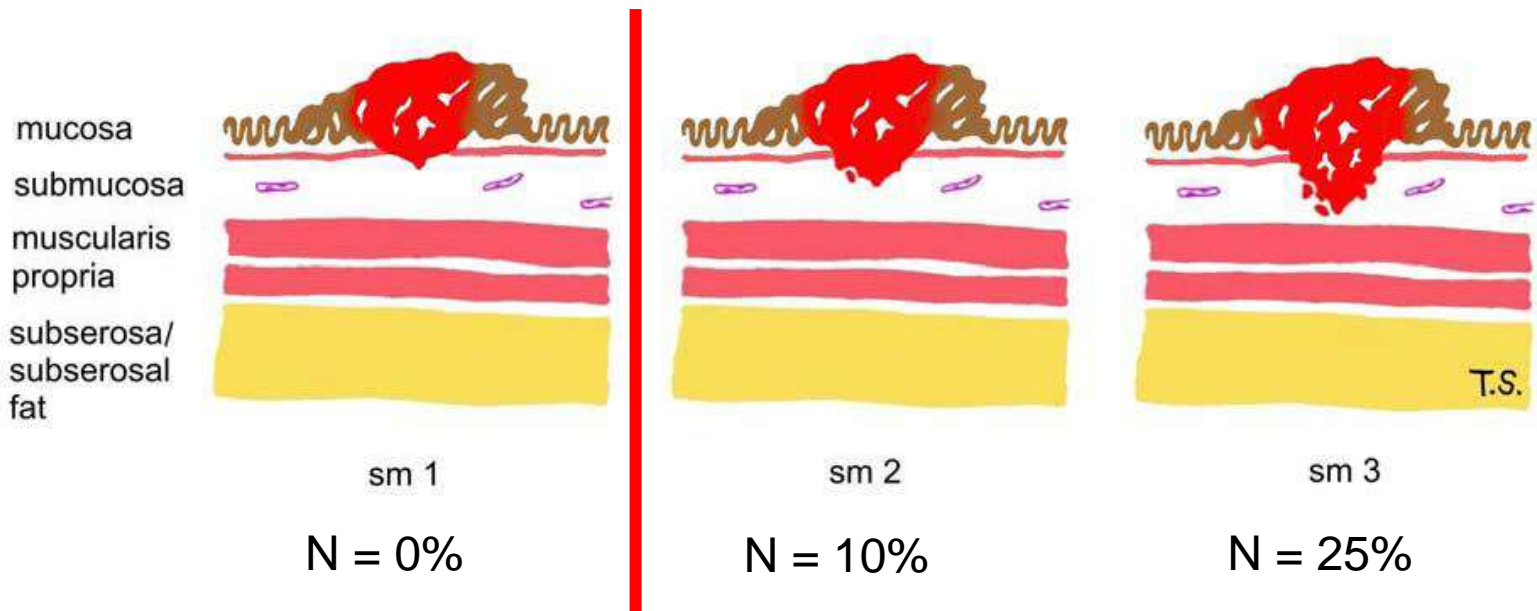


Level 4:  
invasion beyond the  
stalk but above the  
muscularis propria

N = 27%

Cave: G3

# Côlon: Kikuchi classification




Cave: G3

# Complications

- Polypectomie
- Résection de la muqueuse
- Résection par la sousmuqueuse
- Résection de la paroi

Hémorragie

1%




5%

?

Perforation

0.2%



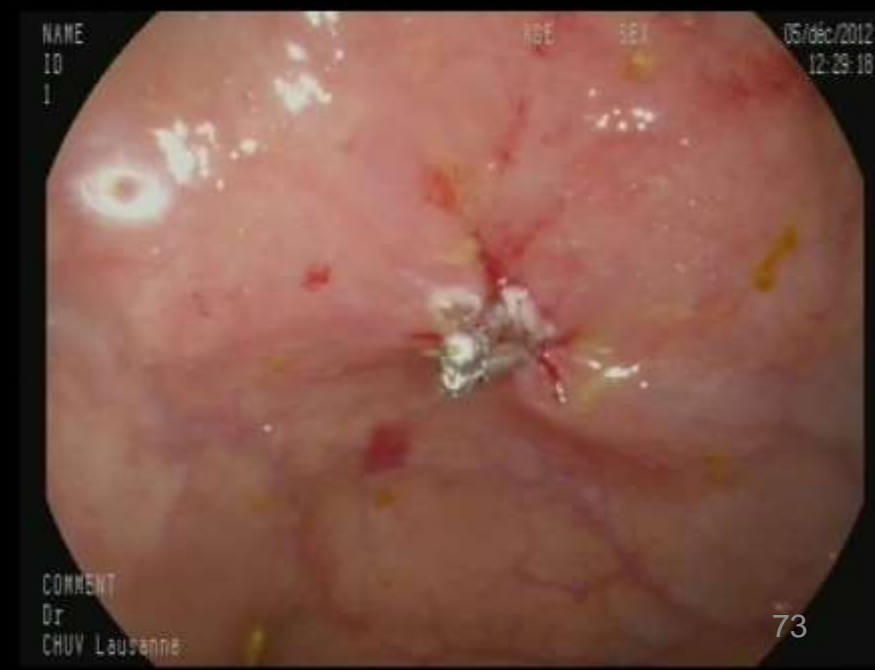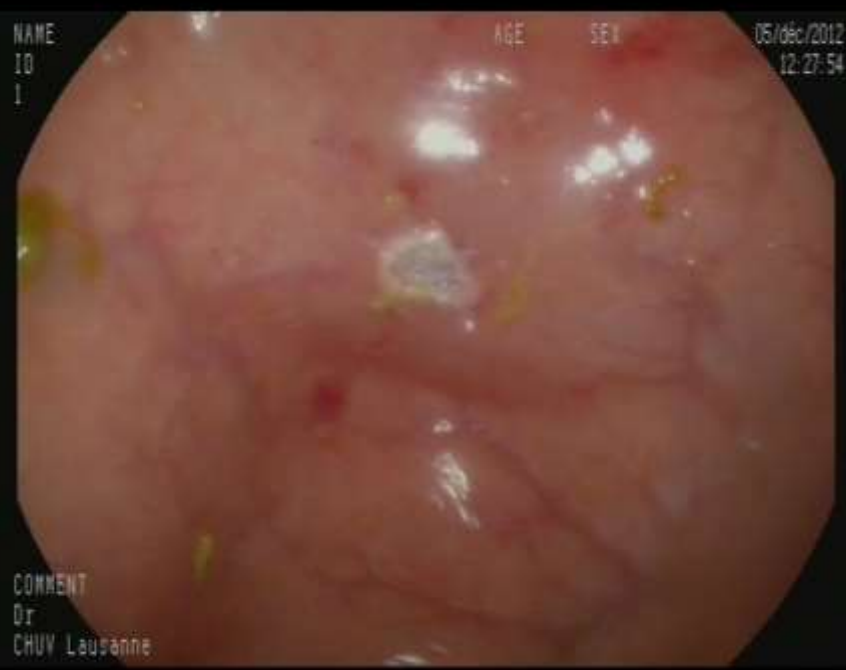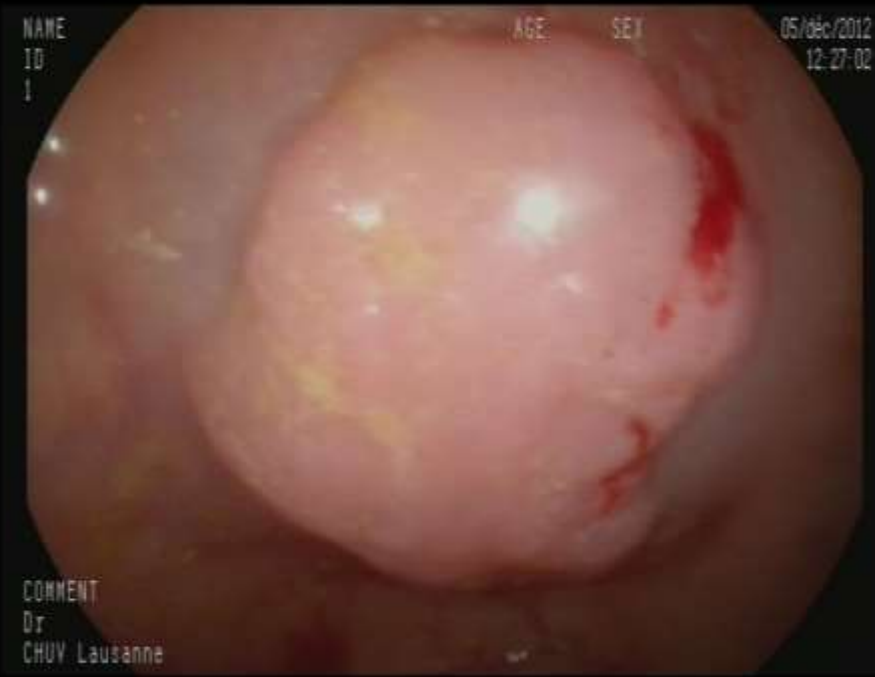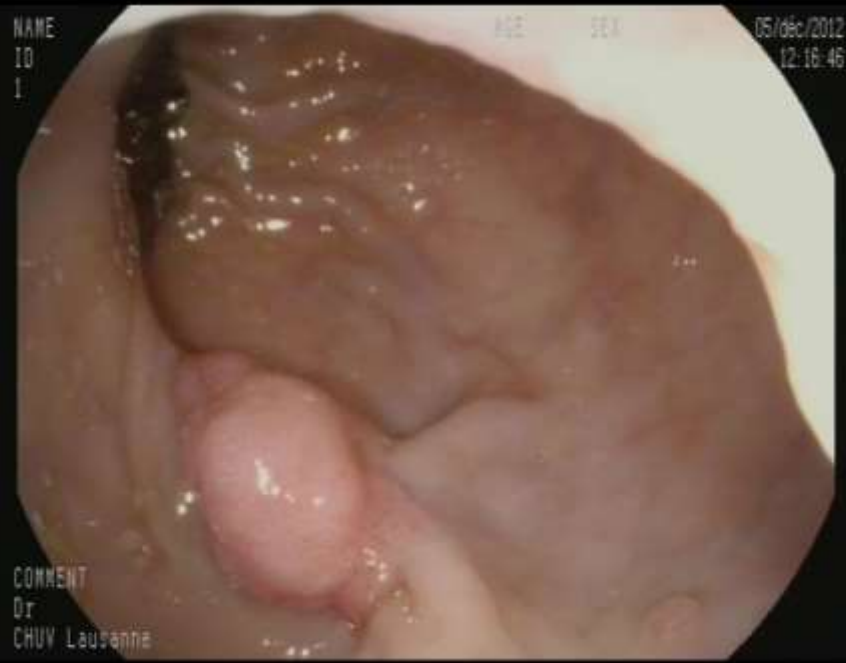5%

?

# Techniques de résection endoscopique

- Polypectomie
  - lésions pédiculées
- Résection de la muqueuse (EMR)
  - lésions sessiles
- Résection par la submuqueuse (ESR)
  - lésions submuqueuses ou lésions sessiles ulcérées
- Résection de la paroi
  - lésions fixées à la submuqueuse







NAME  
ID  
1

AGE

SEX

abût/07/2013

15:43:11

COMMENT  
CHUV Lausanne  
LAUSANNE

